

Circulation

JOURNAL OF THE AMERICAN HEART ASSOCIATION



Assessment of Myocardial Reperfusion by Intravenous Myocardial Contrast Echocardiography and Coronary Flow Reserve After Primary Percutaneous Transluminal Coronary Angiography in Patients With Acute Myocardial Infarction

Wolfgang Lepper, Rainer Hoffmann, Otto Kamp, Andreas Franke, Carel C. de Cock, Harald P. Kühl, Gertjan T. Sieswerda, Jürgen vom Dahl, Uwe Janssens, Paolo Voci, Cees A. Visser and Peter Hanrath

Circulation 2000, 101:2368-2374

Circulation is published by the American Heart Association, 7272 Greenville Avenue, Dallas, TX 75214

Copyright © 2000 American Heart Association. All rights reserved. Print ISSN: 0009-7322. Online ISSN: 1524-4539

The online version of this article, along with updated information and services, is located on the World Wide Web at:

<http://circ.ahajournals.org/content/101/20/2368>

Subscriptions: Information about subscribing to *Circulation* is online at <http://circ.ahajournals.org/subscriptions/>

Permissions: Permissions & Rights Desk, Lippincott Williams & Wilkins, a division of Wolters Kluwer Health, 351 West Camden Street, Baltimore, MD 21202-2436. Phone: 410-528-4050. Fax: 410-528-8550. E-mail: journalpermissions@lww.com

Reprints: Information about reprints can be found online at <http://www.lww.com/reprints>

Assessment of Myocardial Reperfusion by Intravenous Myocardial Contrast Echocardiography and Coronary Flow Reserve After Primary Percutaneous Transluminal Coronary Angiography in Patients With Acute Myocardial Infarction

Wolfgang Lepper, MD; Rainer Hoffmann, MD; Otto Kamp, MD; Andreas Franke, MD; Carel C. de Cock, MD; Harald P. Kühl, MD; Gertjan T. Sieswerda, MD; Jürgen vom Dahl, MD; Uwe Janssens, MD; Paolo Voci, MD; Cees A. Visser, MD; Peter Hanrath, MD

Background—This study investigated whether the extent of perfusion defect determined by intravenous myocardial contrast echocardiography (MCE) in patients with acute myocardial infarction (AMI) treated by primary percutaneous transluminal coronary angioplasty (PTCA) relates to coronary flow reserve (CFR) for assessment of myocardial reperfusion and is predictive for left ventricular recovery.

Methods and Results—Twenty-five patients with first AMI underwent intravenous MCE with NC100100 with intermittent harmonic imaging before PTCA and after 24 hours. MCE before PTCA defined the risk region and MCE at 24 hours the “no-reflow” region. The no-reflow region divided by the risk region determined the ratio to the risk region. CFR was assessed immediately after PTCA and 24 hours later. Left ventricular wall motion score indexes were calculated before PTCA and after 4 weeks. CFR at 24 hours defined a recovery (CFR ≥ 1.6 ; $n=17$) and a nonrecovery group (CFR < 1.6 ; $n=8$). Baseline CFR did not differ between groups. MCE ratio to the risk region was smaller in the recovery group compared with the nonrecovery group ($34 \pm 49\%$ vs $81 \pm 46\%$, $P=0.009$). A ratio to the risk region of $\leq 50\%$ defined an MCE reperfusion group. It was associated with improvement of CFR from 1.67 ± 0.47 at baseline to 2.15 ± 0.53 at 24 hours ($P < 0.001$) and of regional wall motion score index from 2.6 ± 0.5 to 1.9 ± 0.5 at 4 weeks ($P < 0.001$).

Conclusions—Intravenous MCE can be used to define perfusion defects after AMI. Assessment of microcirculation by MCE corresponds to evaluation by CFR. Serial intravenous MCE has the potential to identify patients likely to have improved left ventricular function after AMI. (*Circulation*. 2000;101:2368-2374.)

Key Words: echocardiography ■ blood flow ■ microcirculation ■ myocardial infarction

Treatment of patients with acute myocardial infarction (AMI) aims at early restoration of patency and adequate reflow in the infarct-related artery. However, the objective of reperfusion therapy is not merely restoration of blood flow in the coronary artery but also complete and sustained reperfusion of the myocardium at risk.¹ Studies performed with intracoronary myocardial contrast echocardiography (MCE) have shown that up to 30% of patients undergoing primary angioplasty lack myocardial reperfusion despite recanalization of the infarct-related artery.²⁻⁵ These regions of “no-reflow” may develop because of microvascular disruption, plugging by thromboembolic debris, or endothelial and myocardial edema.⁶ The assessment of perfusion by intracoronary MCE has been shown to provide information on perfusion territories, collateral flow, infarct size, myocardial viability, and success of reperfusion.⁷ Recent advances in ultrasound technology and contrast agents

have enabled the detection of myocardial perfusion after intravenous injection of transpulmonary contrast agents.⁸⁻¹¹ There are no published data on intravenous MCE in patients with AMI. This study was undertaken to assess changes in regional myocardial perfusion in patients with AMI undergoing interventional revascularization. Serial intravenous myocardial contrast echocardiograms were performed before angioplasty and after 24 hours. The MCE results were related to intracoronary Doppler flow measurements for assessment of microvascular circulation and to recovery of left ventricular (LV) function at 4 weeks.

Methods

Patient Population and Study Protocol

This study included 25 patients with first AMI undergoing revascularization by primary percutaneous transluminal coronary angioplasty (PTCA) and stent placement within 6 hours after onset of pain.

Received August 24, 1999; revision received December 9, 1999; accepted December 22, 1999.

From Medical Clinic I, University RWTH, Aachen, Germany (W.L., R.H., A.F., H.P.K., J.v.D., U.J., P.H.); the Department of Cardiology, University Hospital VU, Amsterdam, The Netherlands (O.K., C.C.d.C., G.T.S., C.A.V.); and Core Laboratory (CLIP), Pisa, Italy (P.V.).

Correspondence to Dr Med Wolfgang Lepper, Medical Clinic I, University RWTH Aachen, Pauwelsstraße 30, 52057 Aachen, Germany. E-mail wlep@pcserver.mk1.rwth-aachen.de

© 2000 American Heart Association, Inc.

Circulation is available at <http://www.circulationaha.org>

Inclusion criteria were (1) typical anginal pain lasting >30 minutes and (2) ST-segment elevation of >0.2 mV in ≥ 2 contiguous ECG leads. Patients were part of a multicenter phase II study. A 2D echocardiogram and an MCE was performed before PTCA. Immediately after successful PTCA and stent placement, the coronary flow reserve (CFR) was measured. After 24 hours, the MCE and CFR measurement were repeated. Global and regional wall motion were assessed by 2D echocardiography 4 weeks after PTCA. The study was approved by the local institutional ethics committees. All patients gave written informed consent.

Myocardial Contrast Echocardiography

MCE was performed with the use of NC100100 (Nycomed Imaging AS), a contrast agent consisting of stabilized perfluorocarbon microbubbles (mean diameter 3 to 5 μm). NC100100 powder is reconstituted by adding 2 mL of sterile water, resulting in a solution of 10 μL microbubbles/mL. Up to 3 intravenous injections at a dose of 0.030 μL microbubbles/kg body wt followed by a 10-mL saline flush were given per MCE examination. A digital ultrasound system (HP2500LE or HP5500) was used with harmonic intermittent imaging (1 image per cardiac cycle gated to end-systole) with a phased-array transducer at a mean transmit-and-receive frequency of 1.8 and 3.6 MHz, respectively. A dynamic range of $\approx 80\%$ was used. Transmitted power was adjusted to result in a mechanical index of 0.5 to 0.7. The focus was set at two thirds of the image depth or deeper. Time and lateral gain compensation were adjusted to achieve a homogenous myocardial brightness in the baseline image, so that the myocardium was dark gray, without any black or white in any part. Instrument settings were kept constant throughout the subsequent studies. Before contrast injection, a sequence of images captured by fundamental imaging was recorded. These included 2 apical views (apical 2- and 4-chamber views) and 2 parasternal views (long- and short-axis views) to allow baseline wall motion assessment. MCE image acquisition in the apical 2- and 4-chamber views was started just before contrast injection by switching from continuous to intermittent harmonic imaging mode. All images were stored digitally on magneto optical disk and on super VHS videotape.

Coronary Angiography and Angioplasty

Before catheterization, all patients received 10 000 U of heparin and 500 mg of acetylsalicylic acid intravenously. After the interventional procedure, intravenous heparin was administered continuously for ≥ 24 hours (activated partial thromboplastin time 60 to 80 seconds). All patients received acetylsalicylic acid (100 mg/d) and ticlopidine (250 mg BID). PTCA was performed with standard techniques and included stent placement in all patients.

Images of coronary angiograms were stored on compact disks for offline analysis (QuantCor, CASS II, Siemens). Flow in the infarct vessel was graded by means of the Thrombolysis In Myocardial Infarction (TIMI) flow classification.¹² Collateral flow was graded according to Rentrop et al.¹³

Intracoronary Doppler Flow Measurements

After completion of the interventional recanalization, the guide wire was exchanged for a 0.014-in intracoronary Doppler-tipped flow wire (12 MHz, FloWire, Cardiometrics Inc) to perform intracoronary flow measurements.¹⁴ Placing the tip just proximal to the site of recanalization ensured that the sampling volume corresponded to the site of occlusion. This allowed assessment of flow to the entire region at risk. ECG and blood pressure were monitored continuously. Doppler flow velocity spectra were analyzed online to determine time-averaged peak flow velocity: This was measured at baseline and after intracoronary administration of adenosine (12 to 24 μg). Doppler measurements were repeated 3 times and recorded on super VHS videotape. To allow extrapolation from flow velocity to flow volume, quantitative coronary angiography was performed to determine vessel diameter within the sample volume, that is, 5 mm distal to the tip of the Doppler wire. Doppler-derived flow volume was calculated as described before.¹⁴ CFR was calculated as ratio of maximal flow after adenosine and at baseline. Twenty-four hours

after PTCA, coronary angiography including invasive Doppler measurements was repeated immediately after the follow-up MCE. On the basis of the results of recent studies,¹⁵ we defined a recovery group with a CFR of ≥ 1.6 at 24 hours' follow-up and a nonrecovery group with a CFR of < 1.6 .

Image Interpretation

All ultrasound examinations were evaluated at a core laboratory in Pisa, Italy, by an independent reader blinded to clinical information (P.V.). The MCE images were randomized across time point and patient, and the fundamental images for wall motion assessment were randomized across time point. The triggered images from the first 30 heart beats after the start of each NC100100 injection were presented as a loop and evaluated side by side, together with the corresponding view of the fundamental ultrasound examination. Myocardial opacification demonstrating the presence or absence of perfusion was assessed as either adequate opacification, poor or no opacification (as the result of perfusion defect), not assessable (as the result of technical problems, attenuation, or artifacts), or not performed. Poor or no opacification was defined as delayed, low, or absent contrast enhancement in the evaluated segment in comparison to adjacent segments with adequate opacification. For each MCE examination, the length of the endocardial border corresponding to the part of the myocardium with no or poor opacification was measured in the 2- and 4-chamber views, corresponding to a description by Ito et al.² The sum of both endocardial border length measurements defined the size of the perfusion defect. Measurements before PTCA were performed to determine the risk region. Regions of "no-reflow" were defined as contrast defect at 24-hour follow-up. The region of no-reflow divided by the risk region defined the ratio to the risk region. Corresponding to previous publications,² the ratio to the risk region was used to define an MCE reperfusion group (ratio to the risk region $< 50\%$) and a MCE nonreperfusion group (ratio to the risk region $\geq 50\%$). To quantify myocardial perfusion by MCE, the baseline-subtracted peak gray intensity was determined of the myocardial region with wall motion abnormality before recanalization. Analysis was performed on MCE images before PTCA and at 24-hour follow-up (Quanticon, EchoTec 3D Imaging Systems).

LV wall motion analysis at baseline and after 4 weeks was performed according to the 16-segment model of the American Society of Echocardiography.¹⁶ Global and regional wall motion indexes were calculated according to American Society of Echocardiography definitions. The regional wall motion score was calculated as average wall motion score of the dysfunctional segments at baseline. Thus, the regional wall motion score at follow-up referred to the dysfunctional segments at baseline.

Statistical Analysis

Statistical analysis was performed with the use of the SAS software package. Continuous variables are presented as mean \pm SD and were compared by means of the Student's *t* test or the Wilcoxon test. Dichotomous variables were compared by means of χ^2 statistics or Fisher's exact test. Multivariate linear regression analysis was used to determine clinical parameters with significant impact on MCE results and to determine predictors of LV function at 4 weeks. All univariate parameters with a value of $P < 0.2$ were entered in the analysis. Differences were considered significant at $P \leq 0.05$.

Results

Study Cohort and Procedural Outcome

Primary PTCA including stent placement was successful in all patients. On the basis of CFR measurements at 24-hour follow-up, 17 patients were assigned to the recovery group and 8 patients to the nonrecovery group. The clinical, ECG, angiographic, and intracoronary Doppler flow data of both groups are outlined in Table 1. The 2 groups did not differ with respect to number of diseased vessels or arterial blood

TABLE 1. Clinical, ECG, Angiographic, Hemodynamic, and Intracoronary Doppler Flow Velocity Data of Patients Belonging to Recovery vs Nonrecovery Groups Defined by CFR at 24 Hours

	Recovery Group (n=17)	Nonrecovery Group (n=8)	P
Age, y	59±11	69±9	0.025
Male	10 (58%)	6 (75%)	0.661
Peak creatine kinase, U/L	1510±930	1607±1107	0.820
ST-segment elevation at baseline, mm	9.3±6.4	13.5±10.1	0.225
Time from onset of symptoms to PTCA, h	4.64±1.35	3.69±1.51	0.951
No. of diseased vessels	1.52±0.87	1.75±0.70	0.540
Infarct vessel			
Left anterior descending coronary artery	7/17 (41%)	4/8 (50%)	1.000
Right coronary artery	10/17 (59%)	4/8 (50%)	1.000
Visible collaterals to infarct-related artery	5/17 (29%)	1/8 (12.5%)	0.624
Reference diameter after PTCA, mm	3.14±0.54	3.31±0.71	0.520
Minimal lumen diameter after PTCA, mm	2.90±0.58	3.15±0.69	0.365
TIMI 3 flow after PTCA	16/17 (94%)	4/8 (50%)	0.023
Basal flow after PTCA, mL/s	54.5±23.7	65.0±32.8	0.368
CFR after PTCA	1.64±0.42	1.51±0.40	0.451
Basal flow at 24-h follow-up, mL/s	61.6±34.4	70.4±26.8	0.534
CFR at 24-h follow-up	2.15±0.47*	1.37±0.11	<0.001

* $P<0.001$ vs CFR immediately after PTCA.

pressure and heart rate during the intracoronary flow velocity measurements.

Coronary Doppler Flow to Assess Microvascular Integrity

Immediately after interventional revascularization, recovery and nonrecovery groups had similar flows in the infarct-related artery. At 24-hour follow-up, basal flows were unchanged for both groups. In the recovery group, CFR increased by 23.7% ($P<0.001$), whereas CFR in the nonrecovery group was unchanged (Table 1). Figures 1 and 2 demonstrate examples.

The total endocardial border length of the risk region was 7.0 ± 5.9 cm for all patients, with no difference between recovery and nonrecovery groups (Table 2). Twenty-four hours after recanalization, the recovery group showed a 31.6% reduction of the perfusion defect ($P<0.05$), whereas there was no change in the nonrecovery group. By analysis of the relative changes in perfusion defect size as ratio to the risk region, the nonrecovery group showed a larger region of no-reflow ($81\pm 46\%$) compared with the recovery group ($34\pm 49\%$, $P=0.031$). Figures 3 and 4 demonstrate examples. Baseline-subtracted peak contrast intensity of the dysfunctional segments was similar before PTCA between both groups. However, the recovery group had a significantly greater baseline-subtracted peak contrast intensity after 24 hours (Table 2). Multivariate linear regression analysis demonstrated that infarct location ($r^2=0.4864$, $P<0.001$) and angiographic TIMI 3 flow after revascularization ($r^2=0.3005$, $P<0.005$) have significant impact on MCE ratio to the risk region.

Before PTCA, regional myocardial function did not differ between both groups. At 4-week follow-up, only patients in the recovery group showed a significant improvement of regional and global LV function (Table 2).

MCE to Assess Myocardial Perfusion

Table 3 summarizes clinical, angiographic, CFR, and echocardiographic findings of the reperfusion (ratio to the risk

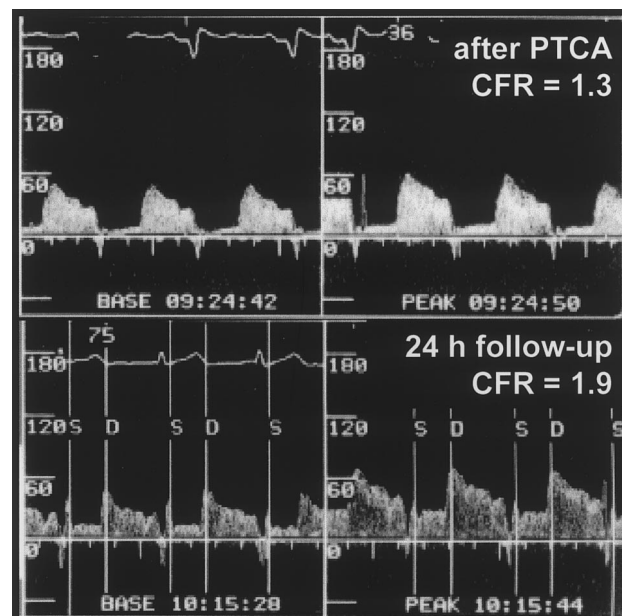


Figure 1. Doppler flow velocity tracings of patient with anterior AMI before and 24 hours after PTCA (same patient as in Figure 3). CFR in infarct-related artery increased from 1.3 immediately after revascularization (top) to 1.9 at 24-hour follow-up (bottom).

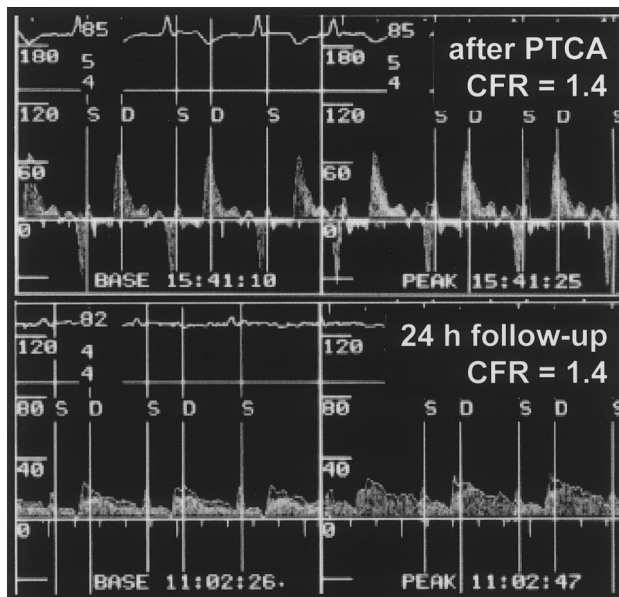


Figure 2. Doppler flow velocity tracings of patient with anterior AMI before and 24 hours after PTCA (same patient as in Figure 4). Upper panel shows coronary flow in infarct-related artery immediately after revascularization with CFR of 1.4. At 24-hour follow-up (bottom), CFR did not change.

region <50%) and the nonreperfusion groups (ratio to the risk region $\geq 50\%$) defined by MCE. In the reperfusion group ($n=13$), CFR increased significantly within 24 hours and was higher compared with the nonreperfusion group ($n=12$) at 24 hours. Improvements of regional and global LV function at 4 weeks were greater in the reperfusion group compared with the nonreperfusion group. Excluding global LV function at baseline and infarct location, multivariate linear regression analysis demonstrated the MCE finding at 24 hours to be the only predictive parameter of global LV function at 4 weeks ($r^2=0.4459$, $P=0.017$).

Discussion

This study describes the use of serial intravenous MCE for assessment of regional myocardial perfusion in patients with

first AMI undergoing interventional revascularization. The results were related to CFR measurements and LV function at 4-week follow-up. The main findings were as follows: (1) There was an increase of the CFR within 24 hours after catheter-based acute revascularization in the majority of patients. (2) Myocardial perfusion evaluated by intravenous MCE corresponded to results on microcirculatory function assessed by CFR. (3) Improvement of myocardial perfusion as indicated either by CFR or intravenous MCE 24 hours after revascularization was predictive for subsequent functional recovery.

Previous Studies

Intracoronary MCE has been demonstrated to have a unique potential to assess microvascular function and integrity. Several recent studies performed with intracoronary MCE in patients with AMI improved the understanding of microvascular alterations present after revascularization.^{2,4,17} Echocardiographic contrast defects obtained before coronary reperfusion of an occluded coronary vessel have been described to denote the region at risk^{2,17} and those obtained after successful coronary reperfusion to denote the no-reflow zones.¹⁸ Microvascular dysfunction could frequently be observed by MCE despite TIMI 3 flow by angiography in the so-called no-reflow zone. However, MCE performed immediately after coronary revascularization may overestimate the salvaged region of postischemic hyperemia. Furthermore, reperfusion may result in a microvascular reperfusion injury.^{7,8,19} To obtain a more reliable analysis of microvascular integrity, MCE should be performed after the microvascular convalescent stage is reached.²⁰ This would require repeated angiography with MCE after a sufficient time interval from the revascularization procedure. Because of the difficulties to perform intracoronary MCE at a later stage and the demanding nature of the technique, intracoronary MCE has not found widespread application for assessment of microvascular integrity after AMI. Recent developments of contrast agents, intermittent harmonic imaging, and a better understanding of the interaction between microbubbles and ultrasound resulted

TABLE 2. Intravenous MCE Data and LV Wall Motion Score Indexes of Patients Belonging to Recovery vs Nonrecovery Groups Defined by CFR at 24 Hours

	Recovery Group (n=17)	Nonrecovery Group (n=8)	P
Endocardial length MCE risk region, cm	5.7 \pm 5.5	9.8 \pm 6.1	0.105
Endocardial length MCE "no-reflow" region, cm	3.9 \pm 5.7*	9.1 \pm 6.1	0.049
MCE ratio to the risk region, %	34 \pm 49	81 \pm 46	0.031
Contrast intensity before PTCA, U	14.9 \pm 10.2	9.8 \pm 7.9	0.162
Contrast intensity after 24 h, U	23.9 \pm 13.7†	11.9 \pm 7.7‡	0.021
RWMI before PTCA	2.7 \pm 0.5	2.8 \pm 0.1	0.707
RWMI after 4 wk	2.0 \pm 0.5§	2.6 \pm 0.4	0.027
GWMI before PTCA	1.6 \pm 0.2	1.9 \pm 0.3	0.015
GWMI after 4 wk	1.4 \pm 0.3	1.8 \pm 0.4	0.011

RWMI indicates regional wall motion score index; GWMI, global wall motion score index.

* $P<0.05$ vs risk region, † $P<0.01$ vs peak contrast intensity before PTCA, ‡ $P=NS$ vs peak contrast intensity before PTCA, § $P<0.001$ vs RWMI before PTCA, || $P<0.001$ vs GWMI before PTCA.

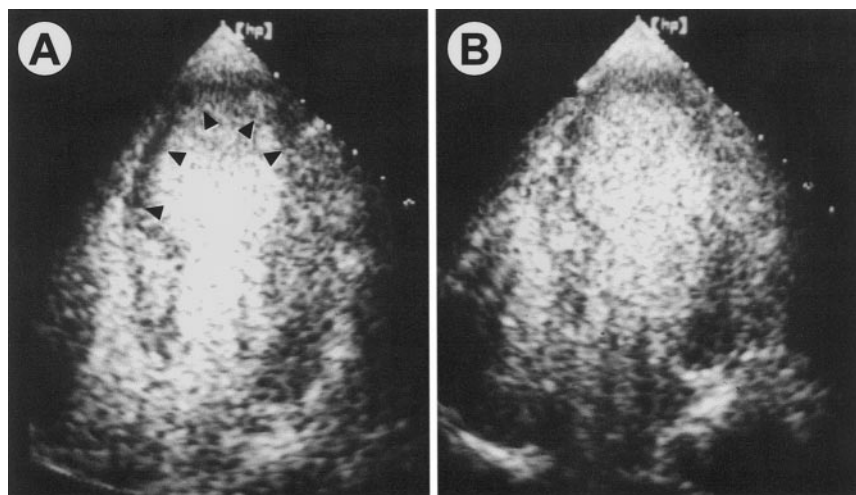


Figure 3. MCE at end systole (apical 4-chamber view) in patient with anterior AMI before PTCA (A) and 24 hours later (B). Sum of endocardial border length corresponding to risk region in 2- and 4-chamber views was measured as 13.8 cm before PTCA and 3.9 cm after 24 hours ("no-reflow" region). Ratio to risk region of 28% indicated significant reduction of perfusion defect (arrows).

in improved myocardial contrast detection even after intravenous contrast application^{11,21,22}

MCE and CFR

Direct intracoronary Doppler measurement of CFR is an established tool for assessment of microvascular function.¹⁴ Recent studies demonstrated CFR of the infarct-related artery to be severely impaired immediately after reperfusion and to recover subsequently.^{19,23} Improvement of CFR after adequate reperfusion may be explained by a greater availability of vasodilating mediator substances after depletion of substances during ischemia.²⁴ In this study, an increase of CFR within 24 hours after acute recanalization was observed in the majority of patients, indicating recovery of myocardial microcirculation. In 8 patients, the CFR remained <1.6. These patients showed a significantly reduced or absent recovery of LV function within 4 weeks. Thus, a low CFR 24 hours after reperfusion was a predictor of a low likelihood of functional improvement. This is in agreement with a recent study demonstrating that recovery of LV function early after AMI could be predicted by measurement of the CFR of the infarct-related artery before and after PTCA.¹⁵ The cutoff value of 1.6 used in this study corresponds to the findings reported by Mazur et al.¹⁵

MCE and CFR developed in a parallel fashion after AMI. Reduction of MCE perfusion defects were associated with improvement of CFR, whereas persistent MCE perfusion defects were associated with unchanged depression of CFR, indicating a relation between microvascular integrity assessed by CFR and by intravenous MCE.

However, it should be noted that MCE and CFR reflect different aspects of regional microvascular circulation. CFR is dependent on a number of factors apart from the microvascular integrity. In the case of stable hemodynamic parameters, it is dominated by the resistance of microcirculation. It reflects the microvascular function of a given perfusion bed irrespective of the size of the myocardial territory supplied by the evaluated coronary artery. Thus, CFR does not allow an estimate of the amount of the endangered myocardium. In contrast, opacification during MCE provides information on the myocardial blood volume of a given region and offers the ability to evaluate the absolute amount of myocardium at risk.

Recovery of LV Function

Serial intravenous MCE before and 24 hours after interventional revascularization had a predictive value for LV recovery at 4 weeks. Patients with a significantly reduced perfusion defect 24 hours after revascularization demonstrated a better

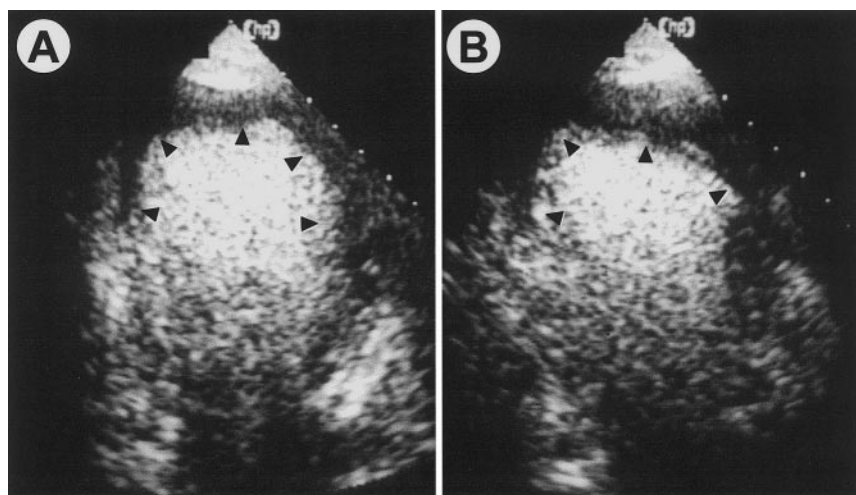


Figure 4. MCE at end systole (apical 2-chamber view) in patient with anterior AMI before PTCA (A) and at 24 hours (B). Sum of endocardial border length corresponding to risk region (arrows) in 2- and 4-chamber views was measured as 18.9 cm before PTCA and 17.0 cm after 24 hours ("no-reflow" region). Ratio to risk region of 90% despite recanalized infarct-related artery indicated poor myocardial reperfusion.

TABLE 3. Clinical, Angiographic, Intracoronary Doppler Flow Velocity Data, and Functional Outcome of Patients Belonging to Reperfusion Group (Reduction of Initial MCE Perfusion Defect $\geq 50\%$ at 24 Hours vs Nonreperfusion Group (Reduction of MCE Perfusion Defect $< 50\%$)

	Reperfusion Group (n=13)	Nonreperfusion Group (n=12)	P
Age, y	58.2 \pm 11.4	67.2 \pm 9.5	0.045
Male	7/13 (54%)	9/12 (75%)	0.411
Infarct location: anterior/inferior	2/11	9/3	0.005
Peak creatine kinase, U/L	1140 \pm 766	1892 \pm 1115	0.060
Time from onset of symptoms to PTCA, h	4.3 \pm 1.5	4.4 \pm 1.4	0.937
TIMI 3 after PTCA	13/13 (100%)	7/12 (58%)	0.015
Visible collaterals	5/13 (38%)	1/12 (8%)	0.160
Basal flow after PTCA, mL/s	59.3 \pm 24.9	52.7 \pm 29.9	0.553
CFR after PTCA	1.67 \pm 0.47	1.48 \pm 0.31	0.289
Basal flow after 24 h, mL/s	71.6 \pm 39.5	56.1 \pm 19.7	0.234
CFR after 24 h	2.15 \pm 0.53*	1.58 \pm 0.30	0.003
RWMI before PTCA	2.6 \pm 0.5	2.8 \pm 0.2	0.135
RWMI after 4 wk	1.9 \pm 0.5†	2.5 \pm 0.4‡	0.003
GWMI before PTCA	1.6 \pm 0.2	1.9 \pm 0.2	0.003
GWMI after 4 wk	1.4 \pm 0.3§	1.8 \pm 0.3	0.003

RWMI indicates regional wall motion score index; GWMI, global wall motion score index.

* $P < 0.0001$ vs CFR immediately after PTCA, † $P < 0.0001$ vs RWMI before PTCA, ‡ $P < 0.05$ vs RWMI before PTCA, § $P < 0.01$ vs GWMI before PTCA, || $P < 0.05$ vs GWMI before PTCA.

LV function at 4 weeks compared with patients showing a persistent perfusion defect. Recent studies performed with intracoronary MCE in patients with an AMI reported similar findings.^{3,4,25} The perfusion defect size determined by intracoronary MCE has been demonstrated to have significant prognostic implications for recovery of LV function. In 90 patients with a patent infarct-related artery, a strong correlation between myocardial contrast score index obtained after intracoronary contrast injection a mean of 8 days after AMI and regional wall motion at 4-week follow-up was demonstrated.⁴ Ito et al³ showed that patients with MCE no-reflow phenomenon had a lower ejection fraction and a greater LV end-diastolic volume at 25-day follow-up. Brochet et al²⁵ studied 28 patients immediately after reflow and 9 days later by MCE. Patients with sustained reflow or improved contrast echocardiographic findings at 9 days exhibited contractile recovery more frequently after 28 days than patients with sustained no-reflow. However, all these studies were performed with intracoronary administration of contrast agents.

Study Limitations

In experimental reperfusion models, an initial decrease in CFR after reperfusion is followed by a period of subsequent recovery lasting up to 1 week.²⁴ In this study, CFR and intravenous MCE were not performed later than 24 hours after reperfusion to assess the full extent of microvascular recovery. Nevertheless, CFR and intravenous MCE performed at 24-hour follow-up were able to discriminate between patients likely to show functional improvement at 4 weeks and those less likely to improve.

In this study, a ratio to the risk region of 50% was used as an arbitrary cutoff value to differentiate between an MCE

reperfusion group and an MCE nonreperfusion group. Recent studies performed with intracoronary MCE have used a lower cutoff value of 25%,² which was also defined arbitrarily.

The evaluation of the echocardiographic images was based on gray-scale tissue imaging. The machine settings used in this study relate to the best knowledge at the time of study initiation. Optimal echocardiographic machine settings for MCE are rapidly evolving and are dependent on the applied contrast agent. Thus, it is very challenging to set up and adhere to a study protocol in a field in which knowledge of how to use an evolving technology is improving very quickly.

The number of patients included in the study was small. Prospective studies with larger numbers of patients are required to assess the clinical role of intravenous MCE for the assessment of myocardial perfusion in AMI.

Clinical Implications

Intravenous MCE with the use of second-generation contrast agents and intermittent harmonic imaging has the potential to noninvasively identify significant microvascular damage with resulting perfusion defects in patients after AMI. Assessment of microvascular integrity by MCE corresponds closely to the evaluation of the microcirculation by CFR. Intravenous MCE may allow the identification of patients with adequate myocardial reperfusion who are likely to have improved myocardial function after AMI.

Acknowledgment

This study was supported by a research grant from Nycomed-Amersham.

References

1. Anderson JL, Karagounis LA, Becker LC, et al. TIMI perfusion grade 3 but not grade 2 results in improved outcome after thrombolysis for

- myocardial infarction: ventriculographic, enzymatic, and electrocardiographic evidence from the TEAM-3 Study. *Circulation*. 1993;87:1829–1839.
2. Ito H, Tomooka T, Sakai N, et al. Lack of myocardial perfusion immediately after successful thrombolysis: a predictor of poor recovery of left ventricular function in anterior myocardial infarction. *Circulation*. 1992;85:1699–1705.
 3. Ito H, Maruyama A, Iwakura K, et al. Clinical implications of the “no reflow” phenomenon: a predictor of complications and left ventricular remodeling in reperfused anterior wall myocardial infarction. *Circulation*. 1996;93:223–228.
 4. Ragosta M, Camarano G, Kaul S, et al. Microvascular integrity indicates myocellular viability in patients with recent myocardial infarction: new insights using myocardial contrast echocardiography. *Circulation*. 1994;89:2562–2569.
 5. Kenner MD, Zajac EJ, Kondos GT, et al. Ability of the no-reflow phenomenon during an acute myocardial infarction to predict left ventricular dysfunction at one-month follow-up. *Am J Cardiol*. 1995;76:861–868.
 6. Kloner R, Ganote CE, Jennings RB. The “no-reflow” phenomenon after temporary coronary occlusion in the dog. *J Clin Invest*. 1974;54:1496–1508.
 7. Sabia PJ, Powers ER, Ragosta M, et al. An association between collateral blood flow and myocardial viability in patients with recent myocardial infarction. *N Engl J Med*. 1992;327:1825–1831.
 8. Sheil ML, Kaul S, Spotnitz WD. Myocardial contrast echocardiography: development, applications, and future directions. *Acad Radiol*. 1996;3:260–275.
 9. Schrope BA, Newhouse VL. Second harmonic ultrasonic blood perfusion measurement. *Ultrasound Med Biol*. 1993;19:567–579.
 10. Porter TR, D’Sa A, Turner C, et al. Myocardial contrast echocardiography for the assessment of coronary blood flow reserve: validation in humans. *J Am Coll Cardiol*. 1993;21:349–355.
 11. Kaul S, Senior R, Dittrich H, et al. Detection of coronary artery disease with myocardial contrast echocardiography: comparison with ^{99m}Tc-sestamibi single-photon emission computed tomography. *Circulation*. 1997;96:785–792.
 12. TIMI Study Group. The Thrombolysis in Myocardial Infarction (TIMI) trial: phase I findings. *N Engl J Med*. 1985;312:932–936.
 13. Rentrop KP, Cohen M, Blanke H, et al. Changes in collateral channel filling immediately after controlled coronary artery occlusion by an angioplasty balloon in human subjects. *J Am Coll Cardiol*. 1985;5:587–592.
 14. Doucette JW, Corl PD, Payne HM. Validation of a Doppler guide wire for intravascular measurement of coronary artery flow velocity. *Circulation*. 1992;85:1899–1911.
 15. Mazur W, Bitar JN, Lechin M, et al. Coronary flow reserve may predict myocardial recovery after myocardial infarction in patients with TIMI grade 3 flow. *Am Heart J*. 1998;136:335–344.
 16. Schiller NB, Shah PM, Crawford M, et al. Recommendations for quantitation of the left ventricle by 2-dimensional echocardiography: American Society of Echocardiography Committee on Standards, Subcommittee on Quantitation of 2-Dimensional Echocardiograms. *J Am Soc Echocardiogr*. 1989;2:358–367.
 17. Kaul S, Glasheen W, Ruddy TD, et al. The importance of defining left ventricular area at risk in vivo during acute myocardial infarction: an experimental evaluation with myocardial contrast 2-dimensional echocardiography. *Circulation*. 1987;75:1249–1260.
 18. Villanueva FS, Glasheen WP, Sklenar J, et al. Characterization of spatial patterns of flow within the reperfused myocardium by myocardial contrast echocardiography: implications in determining extent of myocardial salvage. *Circulation*. 1993;88:2596–2606.
 19. Neumann FJ, Kósa I, Dickfeld T, et al. Recovery of myocardial perfusion in acute myocardial infarction after successful balloon angioplasty and stent placement in the infarct-related coronary artery. *J Am Coll Cardiol*. 1997;30:1270–1276.
 20. Villanueva FS, Camarano G, Ismail S, et al. Coronary reserve abnormalities in the infarcted myocardium: assessment of myocardial viability immediately versus late after reflow by contrast echocardiography. *Circulation*. 1996;94:748–754.
 21. Grayburn PA, Erickson JM, Escobar J, et al. Peripheral intravenous myocardial contrast echocardiography using a 2% dodecafluoropentane emulsion: identification of myocardial risk area and infarct size in the canine model of ischemia. *J Am Coll Cardiol*. 1995;26:1340–1347.
 22. Porter TR, Li S, Kricsfeld D, et al. Detection of myocardial perfusion in multiple echocardiographic windows with 1 intravenous injection of microbubbles using transient response second harmonic imaging. *J Am Coll Cardiol*. 1997;29:791–799.
 23. Ishihara M, Sato H, Tateishi H, et al. Impaired coronary flow reserve immediately after coronary angioplasty in patients with acute myocardial infarction. *Br Heart J*. 1993;69:288–292.
 24. Vanhaecke J, Flameng W, Borgers M, et al. Evidence for decreased coronary flow reserve in viable postischemic myocardium. *Circ Res*. 1990;67:1201–1210.
 25. Brochet E, Czitrom D, Karila-Cohen D, et al. Early changes in myocardial perfusion patterns after myocardial infarction: relation with contractile reserve and functional recovery. *J Am Coll Cardiol*. 1998;32:2011–2017.