

---

# 5

## CHOLINERGIC IMBALANCE IN THE MULTIPLE SCLEROSIS HIPPOCAMPUS

---

*Acta Neuropathologica* 2011, 122(3);313-322

## ABSTRACT

Hippocampal pathology was shown to be extensive in multiple sclerosis (MS) and is associated with memory impairment. In this post mortem study, we investigated hippocampal tissue from MS and Alzheimer's disease (AD) patients and compared these to non-neurological controls. By means of biochemical assessment, (immuno)histochemistry and Western blot analyses, we detected substantial alterations in the cholinergic neurotransmitter system in the MS hippocampus, which were different from those in AD hippocampus. In MS hippocampus, activity and protein expression of choline acetyltransferase (ChAT), the acetylcholine synthesizing enzyme, was decreased, while the activity and protein expression of acetylcholinesterase (AChE), the acetylcholine degrading enzyme, was found to be unaltered. In contrast, in AD hippocampus both ChAT and AChE enzyme activity and protein expression was decreased. Our findings reveal an MS-specific cholinergic imbalance in the hippocampus, which may be instrumental in terms of future treatment options for memory problems in this disease.

Evert-Jan Kooi<sup>1,2</sup>, Marloes Prins<sup>2</sup>, Natasha Bajic<sup>3</sup>, Jeroen A.M. Beliën<sup>1</sup>, Wouter H. Gerritsen<sup>1</sup>, Jack van Horssen<sup>4</sup>, Eleonora Aronica<sup>5</sup>, Anne-Marie van Dam<sup>2</sup>, Jeroen J.M. Hoozemans<sup>1</sup>, Paul T. Francis<sup>3</sup>, Paul van der Valk<sup>1</sup>, and Jeroen J.G. Geurts<sup>2</sup>

<sup>1</sup>Department of Pathology (Neuropathology), VU University Medical Center, De Boelelaan 1117, 1081 HV Amsterdam, The Netherlands. <sup>2</sup>Department of Anatomy and Neurosciences, Neuroscience Campus Amsterdam, VU University Medical Center, van der Boerhorststraat 7, 1081 BT Amsterdam, The Netherlands. <sup>3</sup>King's College London, Wolfson Center for Age-Related Diseases, Guy's Campus, London, SE1 1UL, United Kingdom. <sup>4</sup>Department of Molecular Cell Biology and Immunology, VU University Medical Center, Van der Boerhorststraat 7, 1081 BT Amsterdam, The Netherlands. <sup>5</sup>Department of Neuropathology, Academic Medical Center, University of Amsterdam, Meibergdreef 9, 1105 AZ Amsterdam, The Netherlands.

## INTRODUCTION

It has been shown that 40-65% of patients suffering from multiple sclerosis (MS) experience various degrees of cognitive deterioration.<sup>20,192</sup> Although different cognitive domains may be affected, processing speed and visuospatial memory are most frequently reported abnormal.<sup>20,190,192,427</sup> The hippocampus is critically important for proper memory function,<sup>428</sup> and recent studies have shown that this brain structure is severely affected in MS.<sup>142,144</sup> In the *post mortem* setting, hippocampal lesions were found to be present in a majority of MS patients<sup>141-144</sup> and several *in vivo* magnetic resonance imaging studies also showed high numbers of hippocampal lesions<sup>146</sup>, as well as reduced volume<sup>148,429</sup> and connectivity<sup>430</sup> of the MS hippocampus.

The cholinergic neurotransmitter system plays an essential role in learning and memory function,<sup>431,432</sup> and the hippocampus is a major region of cholinergic input from the basal forebrain.<sup>166</sup> Choline acetyltransferase (ChAT) is the enzyme responsible for acetylcholine synthesis and ChAT activity has been shown to be a reliable marker for cholinergic integrity.<sup>433</sup> In Alzheimer's disease (AD) brains, severe changes in the cholinergic neurotransmitter system have long been recognized.<sup>179,434-439</sup> Degeneration of cholinergic neurons in the basal forebrain results in a decreased cholinergic input (as indicated by a decrease in ChAT activity) in the AD hippocampus.<sup>179,434,435,440</sup> Furthermore, acetylcholinesterase (AChE), the acetylcholine degrading enzyme, is also downregulated in the AD hippocampus.<sup>436,441</sup> Therefore, pharmacological treatment aiming to restore postsynaptic availability of acetylcholine is commonly used as a first-line therapy for symptomatic treatment of memory impairment in AD.<sup>442</sup> Whether similar changes in the cholinergic neurotransmitter system occur in the MS hippocampus is currently unknown.

Therefore, in this *post mortem* study, we investigate different components of the cholinergic neurotransmitter system in the MS hippocampus, and compare these findings to hippocampus tissue of AD patients and non-neurological controls.

## MATERIALS AND METHODS

### Hippocampal tissue

*Post mortem* brain material was obtained from the Netherlands Brain Bank, Amsterdam, The Netherlands. From 15 MS patients, as well as 10 donors without neurological disease, and 10 AD patients, frozen, coronally-cut hippocampal tissue was selected. From a subset of the cases (i.e., 7 controls, 11 MS, and 8 AD), paraffin-embedded material was also available. Non-neurological controls were carefully matched to the MS patient samples for *post mortem* delay, age, sex and Braak stage. Upon neuropathological assessment, the AD cases had Braak scores<sup>443</sup> of 5 or higher and were included to serve as a positive control regarding possible cholinergic changes. Clinical and pathological data of the MS patients, non-neurological controls and AD patients are provided in Table 1.

**Table 1. Clinical data of MS patients, non-neurological controls, Alzheimer's disease patients**

Case	Age (y)	Type of MS	Braak stage	Sex	PMD (h:m)	DD (y)	Cause of death
1	66	PP	0	M	7:30	26	Unknown
2	49	SP	0	M	8:00	25	Pneumonia
3	71	ND	0	M	7:00	26	Pneumonia by aspiration
4	47	SP	0	M	7:15	7	Urosepsis with organ failure
5	76	PP	1	F	9:45	19	Unknown
6	63	SP	0	M	7:05	24	Cardiac arrest after rupture abdominal aorta
7	77	ND	1	F	5:43	U	Respiratory insufficiency with aspiration pneumonia
8	41	SP	0	F	8:25	11	Unknown
9	43	SP	0	M	8:30	9	Pneumonia
10	61	SP	0	M	9:15	18	Euthanasia
11	67	ND	0	F	9:15	U	Unknown
12	71	SP	0	F	10:25	24	Respiratory insufficiency
13	76	ND	0	F	4:40	U	Uremia following a urinary tract infection
14	56	PP	0	F	6:35	U	Unknown
15	44	PP	0	M	12:00	13	Pneumonia
Con	56	-	0	M	9:15	-	Myocardial infarction
Con	80	-	0	M	7:15	-	Cachexia and dehydration
Con	56	-	0	M	14:00	-	Unknown
Con	61	-	0	F	6:50	-	Euthanasia
Con	84	-	1	M	7:05	-	Exacerbation of COPD
Con	80	-	1	F	6:58	-	Pulmonary embolism
Con	62	-	1	F	7:55	-	Euthanasia
Con	66	-	1	F	7:00	-	Heart failure
Con	66	-	0	M	7:45	-	Aneurysm
Con	84	-	1	M	5:35	-	Heart failure
AD	68	-	6	M	6:30	12	Cachexia
AD	81	-	6	F	6:00	4	Pneumonia
AD	87	-	5	F	9:15	8	Congestive heart failure
AD	87	-	6	F	5:00	20	Cachexia
AD	64	-	6	M	7:30	9	Dehydration and cachexia in end-stage AD
AD	73	-	6	F	5:55	16	Unknown
AD	78	-	5	F	8:25	U	Sepsis
AD	84	-	6	M	8:05	13	Unknown
AD	82	-	6	F	4:20	6	Dehydration and cachexia
AD	65	-	6	M	0:59	U	Pneumonia

PMD = post mortem delay; DD = disease duration; Y= years; PP = primary progressive MS; ND = MS subtype not determined; SP = secondary progressive MS; AD = Alzheimer's disease; Con = non-neurological control; M = male; F = female; U = unknown

The study was approved by the institutional ethics review board (VU University Medical Center, Amsterdam) and all donors or their next of kin provided written informed consent for brain autopsy and use of material and clinical information for research purposes.

### **Sampling procedure**

The hippocampal region, including Cornu Ammonis (CA) 1-4, identified on sections stained for proteolipid protein (PLP) (see section Immunohistochemistry) were traced back in the tissue blocks and carved with a scalpel. In order to ensure that only the correct hippocampal areas were isolated for an adequate comparison, cryosections were cut before and after tissue isolation and subsequently stained for PLP. Tissue for biochemical assays and Western blot analyses were isolated separately and were stored at -80°C until subsequent analyses.

### **Hippocampal lesion classification**

As described previously,<sup>142</sup> PLP-stained hippocampal tissue sections were scored for the presence of lesions according to their anatomical localization. Lesions were classified as 1) mixed intrahippocampal-perihippocampal lesions; and 2) isolated intrahippocampal lesions (i.e. specified for CA subfield) and subsequently counted. Furthermore, microglial activation, based on anti-human leukocyte antigen-DR (HLA-DR) staining (see section Immunohistochemistry) was also examined.

### **Choline acetyltransferase (ChAT) activity assay**

Hippocampal tissue homogenates were blinded and samples were analysed for protein content by the Bradford protein assay. Subsequently, a ChAT enzymatic activity assay was performed following the technique used by Fonnum<sup>444</sup> with minor modifications to the protocol.<sup>445</sup> Frozen hippocampal tissue which was stored at -80 °C was homogenised in ice cold homogenization buffer (0.87 mM EDTA, 0.1% Triton X-100, pH 7.0). Samples were analysed for protein content by Bradford protein assay. An incubation mixture (0.4mM <sup>14</sup>C-Acetyl CoA, 1mg/ml BSA, 0.3mM eserine salicylate, 0.6M NaCl, 4mM choline chloride, 0.1M NaH<sub>2</sub>PO<sub>4</sub>, 17.35mM EDTA) was prepared on ice. The experiments were set up with two time points. Each sample was prepared in triplicate. In addition, a total radioactivity control was set up consisting of incubation buffer only. A blank control was set up with only extraction buffer present. For the first time point brain homogenate was added to incubation buffer with a 1:1 ratio, using equal volumes (e.g. 10 µl) for each sample and incubated at 30°C. Just prior to the end incubation, brain homogenate samples were added to incubation buffer for without incubation. All reactions were then quenched with the addition of ice cold dH<sub>2</sub>O. 1 ml of extraction buffer (15% v/v acetonitrile, 85% toluene, 0.5% w/v sodium tetraphenylboron) was added to the experimental samples. Eppendorfs were spun at 13000 rpm for 2 min. 650 µl of the upper phase was transferred into scintillant tubes. Scintillant tubes for the controls were prepared using the blank and total samples. 2 ml of liquid scintillant (OptiPhase 'HiSafe', Perkin Elmer, UK) was added. Tubes were capped and radioactivity was measured in a beta

counter, for 10 min. each. The activity of ChAT was measured as the amount of acetylcholine produced per hour, per mg of total protein (nmol/hr/mg).

#### **Acetylcholinesterase (AChE) enzyme histochemistry**

On hippocampal cryosections (8µm thick) acetylcholinesterase histochemistry was performed using a slightly modified version of the direct coloring Karnovsky-Roots method.<sup>446</sup> In short, slides were fixed for 15 min. with 8% formaldehyde in 0.1M CaCl<sub>2</sub> and pre-incubated for 30 min. in 0.18mM tetra-isopropyl-pyrophosphoramidate in phosphate buffered saline (iso-ompa) to block aspecific staining. Subsequently, sections were incubated in reaction medium (consisting of 6.5 ml iso-ompa, 5 mg acetyl-thiocholine-iodine, 0.5 ml 1M sodium citrate, 1.0ml 30mM copper(II)sulphate, 1.0 ml distilled water and 1.0 ml 5mM potassium ferricyanide) at 37°C for 6 hours to visualise acetylcholinesterase activity. For orientation cell nuclei were stained with 1% methylgreen.

#### **Immunohistochemistry**

Five µm-thick frozen sections were collected on Superfrost Plus glass slides (VWR international; Leuven, Belgium), dried overnight at room temperature (RT) and subsequently fixed in acetone for 10 min. Then, sections were rinsed for 3 x 10 min. with 0.01 M phosphate buffered saline (PBS; pH 7.4) followed by incubation with mouse-anti-human primary antibodies against myelin proteolipid protein (PLP; Clone: Plpc1; mouse IgG2a; 1:500; Serotec, Oxford, UK) diluted in PBS containing 1% bovine serum albumin (BSA) (Roche Diagnostics; Mannheim, Germany) for 1 hour. Subsequently, sections were rinsed with PBS (3 x 10 min.) and incubated with biotin-labeled rabbit anti-mouse immunoglobulins F(ab')<sub>2</sub> (1:500) (DAKO, Glostrup, Denmark) diluted in PBS with 1% BSA for 30 min. Then, sections were rinsed in PBS (3 x 10 min.) and incubated for 1 hour at RT with streptavidin-biotin-peroxidase complexes (1:100; Vectastain; Vector Laboratories Inc., Burlingame, CA, USA). Finally, sections were rinsed with PBS (3 x 10 min) and peroxidase reaction was developed with 3,3'diaminobenzidine-tetrahydrochloridedihydrate (DAB; DAKO, Glostrup, Denmark) as a chromogen. After a short rinse with tap water, sections were counterstained with hematoxylin for 1 min. and intensely washed with tap water for 5 min.

Eight µm-thick paraffin sections were deparaffinized in a series of xylene (4 x 5 min), 100% ethanol, 96% ethanol, 70% ethanol. Endogenous peroxidase activity was blocked by incubating the sections in methanol with 0.3% H<sub>2</sub>O<sub>2</sub> for 30 minutes. In case of primary immunostaining with anti-proteolipid protein (PLP) (mouse IgG2a; 1:3000; Serotec, Oxford, UK) sections were rinsed for 3 x 10 min. with PBS followed by incubation with primary antibodies diluted in PBS containing 1% BSA for 1h. In case of primary immunostaining with anti-HLA-DR, sections were pretreated with microwave antigen retrieval (3 min. at 900W and 30 min. at 180W). After pretreatment, sections were cooled to room temperature, rinsed with PBS (3 x 10 min.) and incubated with anti-HLA-DR (mouse IgG2b; 1:50, generous gift from Dr. Hilgers, VUMC, Amsterdam) diluted in PBS containing 1% BSA for 1 h. Then, sections

were rinsed again with PBS (3 x 10 min) and incubated with EnVision horseradish peroxidase (HRP) complex (DAKO, Glostrup, Denmark) and finally with 3,3' diaminobenzidine-tetrahydrochloridedihydrate (DAB; DAKO, Glostrup, Denmark) as a chromogen. After a short rinse with tap water, sections were counterstained with hematoxylin for 1 min and intensely washed with tap water for 5 min.

For immunostaining with anti-ChAT (AB144P, goat polyclonal, 1:400, Millipore, Billerica, MA, USA) sections were deparaffinized and rehydrated as described above. Subsequently, sections were incubated with 37% formaldehyde for 10 min. and then rinsed with distilled water (2 x 5 min.). Then, sections were rinsed with citrate buffer (pH 6.0) (3 x 10 min.) and finally rinsed overnight in citrate buffer at 4°C. The other day the slides were again rinsed for 2 x 10 min. with citrate buffer and then 10 min. in tris-buffered saline (TBS; pH 7.6). Hereafter, endogenous peroxidase activity was blocked by incubating the sections with TBS with 3% H<sub>2</sub>O<sub>2</sub> for 30 minutes. Then, sections were rinsed with TBS (10 min.) and citrate buffer (2 x 10 min.). Subsequently, sections were pretreated by microwave antigen retrieval (3 min. at 900W and 30 min. at 180W) in citrate buffer. After pretreatment, sections were cooled to room temperature and rinsed with TBS (3 x 10 min.). Then, sections were incubated with 5% normal rabbit serum (DAKO, Glostrup, Denmark) in TBS with 0.5% Triton X-100 (TBS-Tx) for 30 minutes and then with primary antibodies diluted in TBS-Tx containing 2% normal rabbit serum for 2h at RT and subsequently 48h at 4°C. After two days, sections were rinsed again with TBS (3 x 10 min) followed by 1h incubation with biotin-labeled rabbit-anti-goat antibodies (DAKO, Glostrup, Denmark) diluted in TBS-Tx. Subsequently, sections were rinsed in TBS (3 x 10 min.) and incubated for 1h at RT with streptavidin-biotin-peroxidase complexes (1:100; Vectastain; Vector Laboratories Inc., Burlingame, CA, USA) diluted in TBS-Tx. After two rinse steps (10 min.) in TBS sections were rinsed with Tris-hydrochloride (pH 7.6) for 10 min. and then incubated with 3,3'diaminobenzidine-tetrahydrochloridedihydrate (DAB; DAKO, Glostrup, Denmark) as a chromogen. After a short rinse in TBS-hydrochloride (3x), sections were counterstained with hematoxylin for 1 min and intensely washed with tap water for 5 min. For all immunostainings performed, negative controls were prepared by incubation without primary or secondary antibody and gave no immunoreactivity.

#### **Western blot analysis**

For protein analysis, 30 hippocampal sections of 10 µm-thick were isolated from 7 controls, 9 MS and 7 AD patients as described in 'sampling procedure'. Subsequently, tissue was homogenized by incubating the samples with radio-immunoprecipitation assay (RIPA) buffer and protease inhibitors (Sigma-Aldrich, Zwijndrecht, The Netherlands) on ice for 30 min followed by sonification (Branson sonifier, Danbury, CT, USA). The protein concentration was measured with the bicinchoninic acid (BCA) protein assay (Pierce, Perbio Science, Etten-Leur, The Netherlands) as indicated in the user manual, using bovine serum albumin for standard curve. Samples were stored at -80°C until assayed.

Equal amounts of protein (10 µg) were separated on 10% SDS-PAGE gels (Bio-Rad Laboratories, CA, USA) and transferred to PVDF membranes (Bio-Rad). After blocking in PBS and Odyssey blocking buffer (1:1) (LI-COR Biosciences, Lincoln NE, USA), membranes were incubated with primary antibody anti-AChE (PAB6747, goat polyclonal, 1:2000, Abnova, Walnut, CA, USA) overnight at 4°C. Then, membranes were rinsed in PBS containing 0.1% Tween-20 (4 x 5 min.) and incubated with donkey-anti-goat-IRDye® 800CW infrared dye (1:15000) (LI-COR Biosciences) diluted in PBS, Odyssey blocking buffer (1:1), 0,1% Tween-20 and 0.01% SDS for 1h at RT. Finally, the membranes were rinsed in PBS and 0.1% Tween-20 (4 x 5 min.), 3 times in PBS and then membranes were analyzed using a Odyssey Infrared Imaging system (LI-COR Biosciences) and relevant signal intensity was quantified with LI-COR analysis software. Molecular weight and predicted band size of AChE is 68 kDa. After this, the membranes were incubated (overnight at 4°C) with the primary antibody anti-lactate dehydrogenase (1:20000) (LDH; ab52448, rabbit monoclonal, Abcam, Cambridge, UK). Molecular weight and predicted band size of LDH is 37 kDa. After this, membranes were incubated with goat-anti-rabbit-IRDye® 800CW infrared dye (1:15000) (LI-COR Biosciences) diluted in PBS, Odyssey blocking buffer (1:1), 0,1% Tween-20 and 0.01% SDS for 1h at RT and analyzed as describe above and subsequently relative AChE protein expression was quantified.

#### **Quantification of (immuno)histochemical stainings**

(Immuno)histochemically stained sections were scanned with a Mirax slide scanner system (3DHISTECH, Budapest, Hungary). Digital images scanned with a 20x objective were captured in three randomly selected areas of each of the hippocampal subfields (CA1, CA3-2 and CA4) for ChAT immunostainings and AChE histochemical stainings. As already indicated above, paraffin-embedded material was available from 7 control, 8 AD and 11 MS hippocampi and this material was therefore immunohistochemically stained for ChAT. For each investigated hippocampal subfield (i.e. CA1, CA2-3 and CA4), three randomly selected areas were captured for subsequent quantification. This means that for controls a total of 21 (3 x 7), for AD 24 (3 x 8) and for MS 33 (3 x 11) randomly chosen areas were captured. For the control, AD and MS hippocampal sections (frozen) on which AChE enzyme histochemistry was performed, respectively 30 (3 x 10), 30 (3 x 10) and 45 (3 x 15) randomly selected areas from each hippocampal subfield were captured for subsequent quantification. The (immuno) reactivity of the stainings was scored in a blinded fashion with respect to the presence of demyelinated lesions in order to avoid potential bias (e.g. by the expectation that lesional areas should show more pronounced cholinergic system changes). However, differences in terms of cholinergic alterations between lesional and perilesional or non-lesional areas was retrospectively assessed. The relative amount of staining was analyzed using a for this staining tailor-made batch mode ImageJ macro as previously described.<sup>447</sup> ImageJ is freely available at: <http://rsb.info.nih.gov/ij/index.html> (U.S. National Institutes of Health, Bethesda, MD, USA).



### Statistics

GraphPad Prism software (San Diego, CA, USA) was used for the statistical analyses. In case of normal distribution of data, analysis of variance (ANOVA) with Dunnett's correction for multiple comparisons was used to compare differences among the control, MS and AD groups, with the control group as a reference point. When normality was not found, the non-parametric Kruskal-Wallis test was used with a Dunn's correction for multiple comparisons. Results were considered significant when  $p < 0.05$ .

## RESULTS

### Hippocampal demyelination

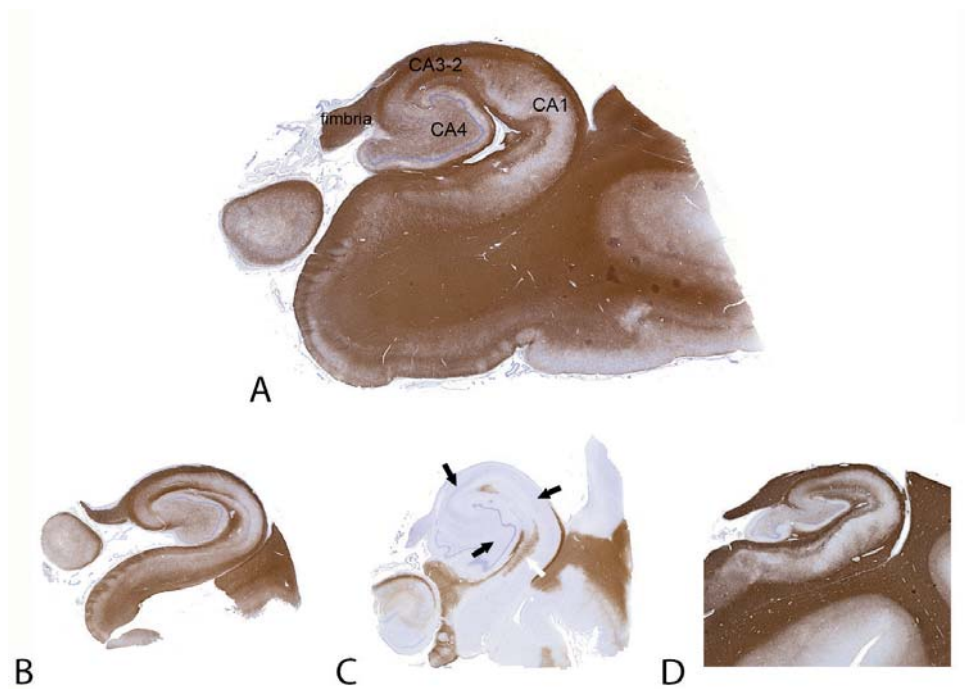
None of the control or AD hippocampus samples showed any sign of demyelination (Fig. 1a, b). As for MS, 12 out of 15 MS hippocampus samples were partly or completely demyelinated (Fig. 1c). More specifically, a total number of 25 lesions were found of which 14 lesions were mixed intrahippocampal-perihippocampal lesions and 11 lesions were isolated intrahippocampal lesions. Only three MS hippocampi showed no demyelination (Fig. 1d). This is in line with our previous observations<sup>142</sup> and with *post mortem* findings of other groups.<sup>141,144</sup> In addition, as described in detail before,<sup>142</sup> our MS samples indicated slightly enhanced microglia activation, as reflected by increased HLA-DR immunopositivity, in hippocampal areas where the myelin was still intact (data not shown). Furthermore, as expected based on the literature,<sup>142-144</sup> no lymphocyte/macrophage infiltration was found in the MS hippocampal lesions.

### Hippocampal ChAT activity and protein expression

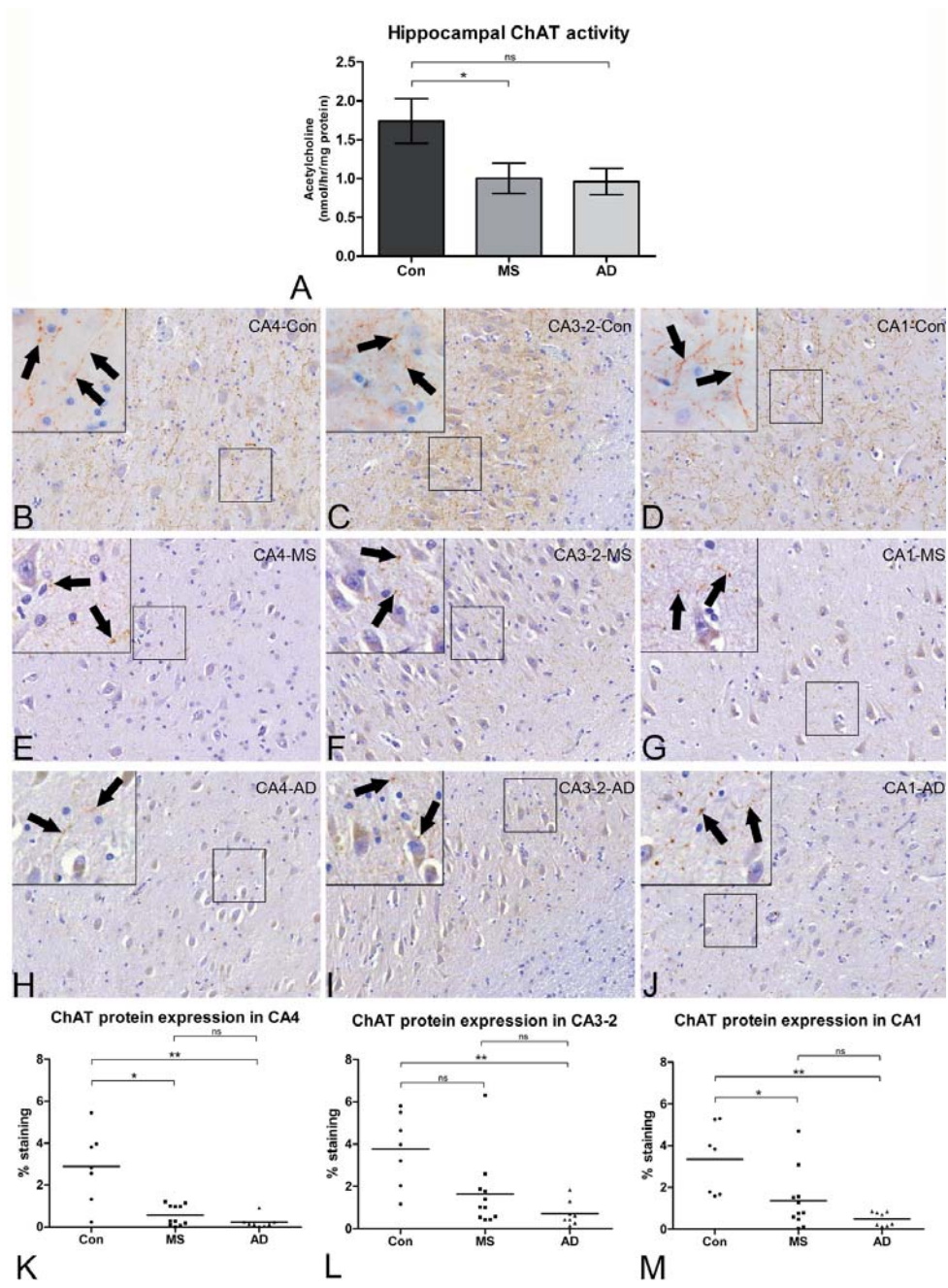
The biochemical assay revealed differences in mean hippocampal ChAT activity levels among the control, MS and AD groups (Kruskal-Wallis;  $p = 0.026$ ). Post hoc, a mean reduction in ChAT activity level of 43% was found in MS hippocampi compared to controls (Fig. 2a; MS vs. Con, mean of 1.00 vs. 1.74 nmol acetylcholine/hr/mg protein;  $p < 0.05$ ). A mean reduction of 45% was found in AD hippocampi compared to controls (Fig. 2a; AD vs. Con, mean of 0.96 vs. 1.74 nmol acetylcholine/hr/mg protein; not significant after Dunn's correction).

Compared to control hippocampus (Fig. 2b-d), immunohistochemical staining for ChAT was reduced in the different hippocampal subfields (CA4, CA3-2 and CA1) in MS (Fig. 2e-g) and AD (Fig. 2h-j). Subsequently, detailed quantification of digitized images revealed a significant and substantial decrease in ChAT immunoreactivity in CA4 in MS (mean: 80% reduction) and AD hippocampi (mean: 92% reduction) (Fig. 2k, Kruskal-Wallis;  $p = 0.0023$ ; after correction: Con vs. MS:  $p < 0.05$  and Con vs. AD:  $p < 0.01$ ). Although less prominently, ChAT immunoreactivity was also decreased in CA3-2 in MS (mean: 57% reduction) and AD hippocampus (mean: 81% reduction) (Fig. 2l, Kruskal-Wallis;  $p = 0.0035$ ; after correction: Con vs. MS: not significant and Con vs. AD:  $p < 0.01$ ). Finally, ChAT immunoreactivity was

decreased in CA1 in MS (mean: 59% reduction) and in AD (mean: 85% reduction) (Fig. 2m, Kruskal-Wallis;  $p = 0.0019$ ; after correction: Con vs. MS:  $p < 0.05$  and Con vs. AD:  $p < 0.01$ ). Retrospective examination of the MS samples showed that the decrease in ChAT immunoreactivity was present irrespective of demyelination (data not shown).



**Figure 1. Hippocampus anatomy and hippocampal demyelination of the MS samples.** Hippocampus tissue from controls, AD and MS patients were immunohistochemically stained for anti-proteolipid protein and revealed (A) as expected, no sign of demyelination in any of the control hippocampus samples. Cornu Ammonis subfields of the hippocampus (CA4, CA3-2, CA1), as well as the fimbria, are indicated. (B) None of the AD hippocampus samples showed any demyelination, (C) while 12 out of 15 MS patients showed demyelinated lesions. Black arrows indicate demyelination in CA4, CA3-2 and CA1. The white arrow indicates a small preserved area of normal myelination in CA1. (D) 3 out of 15 MS hippocampi were not affected by demyelination.



◀ **Figure 2. Reduced ChAT activity and ChAT protein expression in MS hippocampus.** (A) Statistically significant differences among the three different groups were found regarding the hippocampal choline acetyltransferase (ChAT) activity (Kruskal-Wallis:  $p = 0.026$ ). In MS hippocampus compared to control hippocampus, a mean reduction in ChAT activity of 43% was found (after Dunn's correction:  $p < 0.05$ ). In AD hippocampus compared to control hippocampus, a mean reduction of 45% was found in ChAT activity (after Dunn's correction: not significant). (B-D) Non-neurological control hippocampus immunohistochemically stained with anti-ChAT, revealed ChAT immunopositive neurites (arrows in the insets) in CA4 (B), CA3-2 (C) and CA1 (D). (E-G) In all MS hippocampal subfields (E: CA4, F: CA3-2, G: CA1), ChAT immunopositivity was clearly decreased as compared to control tissue, although bead-like varicosities were occasionally observed (arrows in the insets). (H-J) In AD hippocampus, a decrease of ChAT immunopositivity was also found in CA4 (H), CA3-2 (I) and CA1 (J), with occasional immunopositive bead-like varicosities (arrows in the insets). (K-M) Quantification of ChAT immunostainings revealed reductions of the amount of staining in MS and AD hippocampus in (K) CA4 (Con vs. MS:  $p < 0.05$ ; Con vs. AD:  $p < 0.01$ ), (L) CA3-2 (Con vs. MS: not significant; Con vs. AD:  $p < 0.01$ ) and (M) CA4 (Con vs. MS:  $p < 0.05$ ; Con vs. AD:  $p < 0.01$ ). Original magnifications: (B-J) 200x and 630x (insets). Error bars indicate S.E.M. \* $p < 0.05$ , \*\* $p < 0.01$ , ns = not significant.

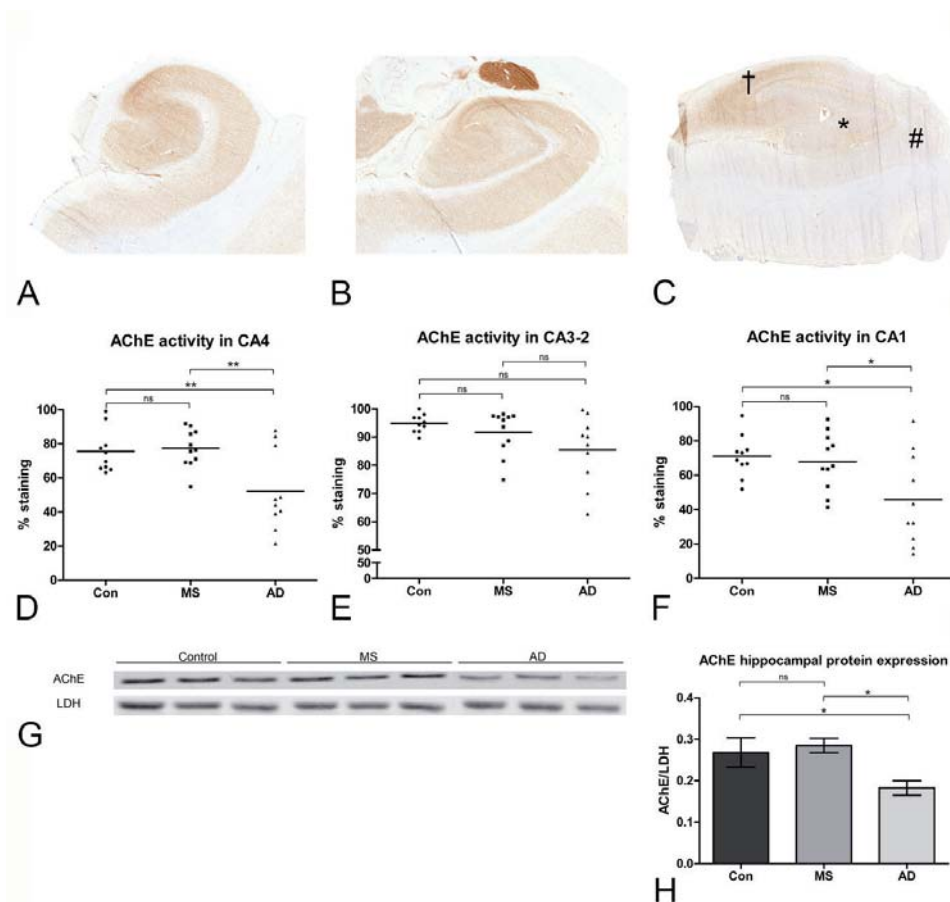
### Hippocampal AChE activity and protein expression

Enzyme histochemistry for AChE revealed no differences in the reaction product formed in the different hippocampal subfields when comparing control (Fig. 3a) and MS (Fig. 3b) hippocampus, indicating an unaltered AChE activity in MS hippocampus. In line with previous results,<sup>436</sup> the reaction product was decreased in AD hippocampus (Fig. 3c). Digital analyses confirmed no differences in the reaction product in MS and control hippocampus in all hippocampal subfields (Fig. 3d-f). Retrospectively, examination of the MS samples indicated that lesional areas did not differ from non-lesional areas in terms of AChE enzyme activity (data not shown). In hippocampus tissue of AD patients, decreased AChE activity was found in CA4 and CA1 (Fig. 3d, f;  $p < 0.01$  and  $p < 0.05$ , respectively). Subsequent Western blot analysis confirmed decreased protein expression levels of AChE in AD hippocampus (Fig. 3g, h;  $p < 0.05$ ), but no differences in AChE protein expression in MS and control hippocampus (Fig. 3g, h).

### DISCUSSION

In the current study, a clear reduction of ChAT activity and ChAT protein expression was found in the MS hippocampus, with unchanged AChE protein expression levels and enzyme activity, which is in line with a recent positron emission tomography study.<sup>448</sup> Our findings suggest that a selective imbalance exists in the hippocampal cholinergic neurotransmission of MS patients, with reduced synthesis of acetylcholine but an unaltered degradation of the neurotransmitter. This imbalance was not found in AD.

Cholinergic neurons in se are not localized within the human hippocampus, and this brain structure receives its main cholinergic input from the basal forebrain.<sup>166</sup> The basal forebrain consists of several nuclei: the cholinergic neurons in the nucleus basalis of Meynert and the horizontal limb of the diagonal band nucleus mainly innervate the olfactory bulb, the amygdala and the cerebral cortex,<sup>166</sup> whereas the cholinergic neurons associated with the vertical nucleus of the diagonal band and the medial septal nucleus mainly innervate the hippocampal complex.<sup>166</sup> The cholinergic pathways extending from the vertical nucleus



**Figure 3. Unchanged AChE activity and protein expression in MS hippocampus.** The activity of AChE as reflected by the amount of reaction product formed was equal in (A) non-neurological control hippocampus and (B) MS hippocampus in all hippocampal subfields. In contrast, in (C) AD hippocampus, the formed reaction product was clearly decreased in CA4 (\*) and CA1 (#), but not in CA3-2 (†), indicating a decreased activity of AChE in these areas. (D-F) Quantification of the reaction product formed by AChE in the (D) CA4 hippocampal subfield indicated differences among the three groups (ANOVA:  $p = 0.003$ , Dunnet correction revealed Con vs. AD and MS vs. AD:  $p < 0.01$ ; Con vs. MS: no significant difference). For the CA3-2 subfield (E), no differences were found between the three groups (Kruskal-Wallis:  $p = 0.175$ ). For the CA1 subfield (F) differences among the three groups were found (ANOVA:  $p = 0.013$ , Dunnet correction revealed Con vs. AD and MS vs. AD:  $p < 0.05$ ; Con vs. MS: no significant difference). (G) Representative western blot of 3 control, 3 MS and 3 AD samples indicated decreased protein expression of AChE in AD hippocampus, but not in MS hippocampus tissue. (H) Quantification of protein expression levels of AChE of all samples included indicated significant differences among the three different groups (ANOVA:  $p = 0.015$ , Dunnet correction revealed Con vs. AD and MS vs. AD:  $p < 0.05$ ; Con vs. MS: no significant difference). Error bars indicate S.E.M. \* =  $p < 0.05$ , \*\* =  $p < 0.01$ , ns = not significant.



and the medial septal nucleus predominantly travel within the fornix. Of interest, in a *post mortem* study by Huitinga et al.<sup>286</sup> it was reported that the hypothalamus and adjacent fibre bundles, including the fornix, were affected by (active) demyelination in 16 out of the 17 MS patients studied. It is, therefore, tempting to speculate that demyelinating processes in these areas, co-occurring with axonal damage and loss,<sup>304</sup> lead to a cholinergic deficit within the MS hippocampus. However, we were unfortunately not able to investigate lesions in the fornix of the MS patients included in this study, therefore future studies are warranted to investigate this possible correlation. Interestingly, hippocampal cholinergic deficits were found both in demyelinated and non-demyelinated MS hippocampi, although our sample size of non-demyelinated MS hippocampi was low (n=3) to definitively conclude that cholinergic changes are completely lesion-independent. The fact that demyelination and degenerative changes in the neuropil are not necessarily coupled processes in MS was also shown by a *post mortem* study by Wegner et al.<sup>449</sup> who found an overall lesion-independent neocortical thinning of ~10% in MS brains indicating that other mechanisms than cortical demyelination may contribute to grey matter pathology in MS.

As reported extensively in AD literature,<sup>179,434–439</sup> and replicated in this study (although not statistically significant for ChAT activity, probably due to a small AD sample size), our study now also implicates a decreased cholinergic input in the hippocampus of MS patients. As the cholinergic neurotransmitter system has an important role in learning and memory function,<sup>431,432</sup> decreased cholinergic function within the MS hippocampus may be expected to contribute to these memory complaints as experienced by a significant proportion of the MS patients.<sup>20,190,192,427</sup> Indeed, although medical information was sparse for our *post mortem* study, cognitive deficits had been specifically reported in the majority of the MS cases included in this study. Future studies investigating hippocampus-dependent cognitive disturbances in MS patients should now be set up in order to study direct causal relationships with the cholinergic abnormalities found in the current study. Interestingly, a magnetic resonance imaging study indicated that cholinergic pathways are more heavily affected in MS patients who scored worse on visuospatial memory tests.<sup>450</sup>

Pharmacological manipulation of the cholinergic system, by elevating the postsynaptic acetylcholine content using acetylcholinesterase inhibitors, has repeatedly been proven to be successful in AD<sup>442</sup> in (temporarily) restoring learning and memory function. First tentative explorations in an animal model of MS<sup>124,451</sup> and in a small clinical trial on MS patients<sup>452</sup> showed beneficial effects in cognitive performance following the use of acetylcholinesterase inhibitors. Additionally, the use of the acetylcholinesterase inhibitor rivastigmine was found to enhance functional brain adaptive changes related to cognitive processing in MS patients.<sup>453</sup> Our neuropathological and neurochemical findings indeed verify that extensive, and possibly treatable, abnormalities are present in the MS hippocampus. However, our data also show that, compared to AD, MS cases have an imbalance of acetylcholine producing and degrading enzymes.

In MS, hippocampal lesions lack lymphocyte/macrophage infiltration.<sup>142-144</sup> Hence, it is unlikely that our Western blot and enzyme activity results have been influenced by major differences in cellularity. What does cause this difference in the cholinergic system between the two neurodegenerative diseases, and how it may possibly affect treatment schemes, is at present unclear and should be focus of future investigation. Furthermore, as a recent microarray-based study<sup>141</sup> found changes in the glutamate neurotransmitter system in the MS hippocampus, it will also be interesting to see how abnormalities in different neurotransmitter systems may cooperate in the development of cognitive decline in MS.

#### ACKNOWLEDGEMENTS

E-JK and the MS Center Amsterdam are supported by the Dutch MS Research Foundation (grant numbers 02-498MS, 06-587MS and 09-358c). Furthermore, we thank Prof. Dr. H.J. Groenewegen for reading the manuscript.

#### CONFLICTS OF INTEREST

The authors declare that they have no conflict of interest.

