

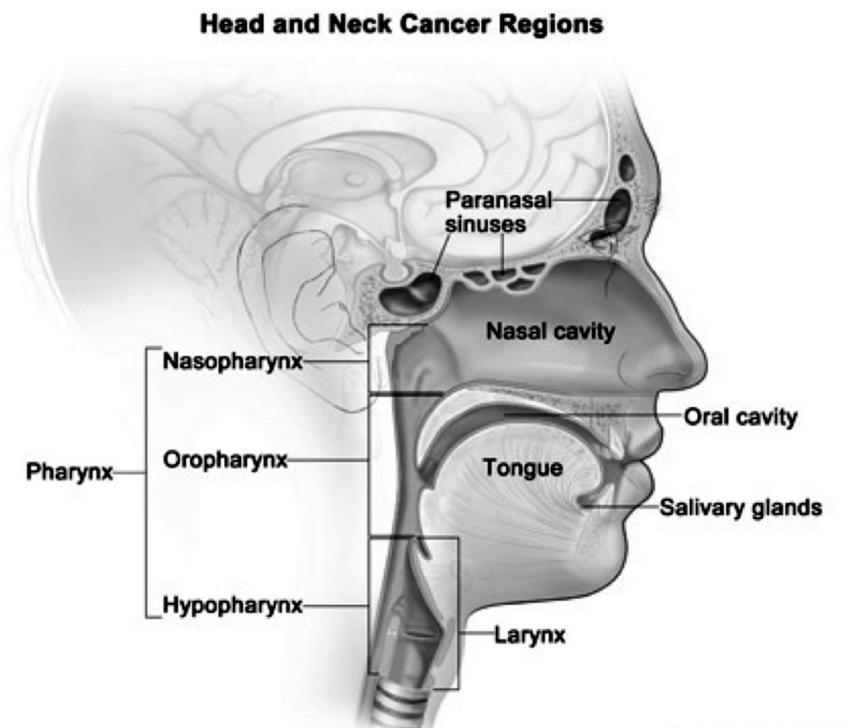
Chapter 1

Introduction

Introduction

The term head and neck cancer (HNC) is used to describe a wide range of malignant tumors of the upper aerodigestive tract, most commonly arising in the oral cavity, pharynx and larynx. This thesis focuses on the treatment of tumors arising from the epithelial membranes of these regions, called squamous cell carcinomas (SCC), representing the vast majority of HNC. Tumors originating in the salivary glands or the paranasal sinuses are also classified as HNC, but account for only a minority of cases.

HNC makes up around 5% of all malignancies [1]. In 2013, in the Netherlands almost 3000 patients were diagnosed with, and 875 patients died of, HNC [2]. The main risk factors for HNC are the use of tobacco and alcohol. More recently, the incidence of oropharyngeal cancer caused by the human papillomavirus (HPV) is rising, especially in the Western World [3].



For the National Cancer Institute © 2012 Terese Winslow LLC, U.S. Govt. has certain rights

Treatment

Surgery and radiotherapy (with or without chemotherapy) are the main treatment modalities for HNC. About one-third of patients present with early stage disease; for these patients single modality treatment by surgery or radiotherapy is usually sufficient, with the choice depending on the expected morbidity of the available treatments.

For patients with locally-advanced stage disease, which is the focus of this thesis, treatment is intensive and usually multimodal [4]. Initially, surgical resection of the primary tumor and lymph node regions, combined with radiation therapy was the mainstay of treatment. Later studies showed that the addition of chemotherapy to postoperative radiotherapy improved overall survival, particularly when there are positive surgical resection margins and/or extranodal spread [5]. In the 1990s, after the Veterans Affairs laryngeal preservation study showed comparable survival outcomes between total laryngectomy and induction chemotherapy followed by radiotherapy (RT), treatment of advanced laryngeal cancer shifted away from surgery towards organ preservation strategies like chemo-radiotherapy (CRT) [6]. Other studies showed the superiority of combining (primary) radiotherapy with chemotherapy compared to radiotherapy alone [7]. Nowadays concomitant CRT is considered standard treatment in locally-advanced stage HNC when organ preservation is considered possible [8].

Toxicity

Treatment of HNC causes toxicity, the characteristics of which depend on the treatment technique as well as on the location and extent of the tumor. Surgery may lead to functional and cosmetic defects, as well as complications such as pain and wound healing problems. Radiotherapy causes acute and late side effects in almost all patients, due to irradiation of the surrounding healthy tissue [9]. The organs at risk (OARs) in the head and neck region at risk for RT damage include the (unaffected) mucosa, salivary glands, swallowing structures, spinal cord, oral cavity with taste buds, mandible, thyroid gland, and more cranially the brainstem, temporal lobes, optic system and pituitary gland. Although the degree of damage (and resulting toxicity) of the OARs is in large part directly related to the radiation dose, the relationship between dose and response/toxicity is complicated and incompletely understood. This is illustrated by the fact that different normal tissue complication probability (NTCP) models are reported in the literature [10].

Acute toxicity may arise either during and/or up to 3 months after radiotherapy and is caused by damage to the fast responding/dividing tissues [11]. One of the most important radiation-induced acute problems is mucositis, giving rise to pain and swallowing problems, leading to weight loss and subsequent weakening of the patient. Other acute side effects are dermatitis, loss of taste, hoarseness, xerostomia and sticky saliva. Treatment intensification, like accelerated radiotherapy (given over a shorter period of time) or combining radiotherapy with chemotherapy generally worsens these side effects [12]. Chemotherapy by itself also has side effects, including nausea and vomiting, and hematological, renal and neurological toxicity.

Late side effects caused by radiotherapy continue or develop at least 3 months after treatment completion. Some of these diminish over time but some are permanent. The most important side effects are xerostomia as a result of salivary gland damage, and dysphagia due to swallowing muscle impairment. Other late sequelae may include fibrosis, hypothyroidism and (osteo)radionecrosis. Both acute and late toxicity can give rise to CRT-related side-effects that can adversely affect certain patient-reported quality of life domains [13].

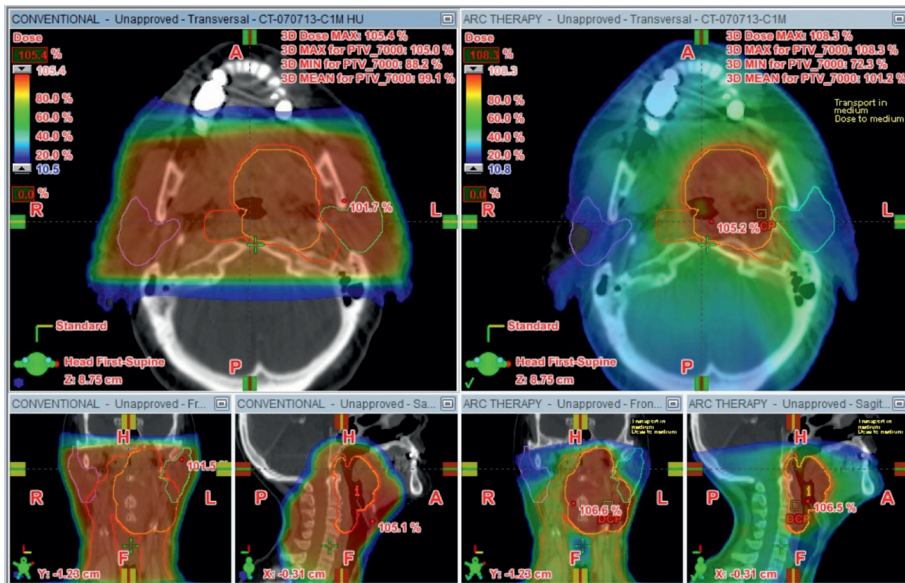
Radiotherapy

Techniques

Initially patients with HNC were treated with conventional radiotherapy, using two opposing lateral fields to treat the upper neck and a lower anterior field for the supraclavicular region. Except for the spinal cord that was shielded after 40-46 Gy, adequate sparing of other OARs was often not possible, leading to significant and permanent side effects. Due to the introduction of computed tomography (CT) based contouring and increased computational power, three-dimensional (3D) conformal radiotherapy entered clinical practice, using forward planning to encompass a 3D target volume and improve sparing of selected organs like the parotid gland [14, 15].

At the end of the twentieth century, fixed-beam intensity modulated radiotherapy (IMRT) became available. IMRT was defined in 2001 by the Intensity Modulated Radiation Therapy Collaborative Working group as “an advanced form of 3D-CRT using non-uniform radiation beam intensities incident on the patient that have been determined using various computer-based optimization techniques” [16]. The difference with 3D conformal radiotherapy is that IMRT optimization aims to achieve a pre-specified dose prescription with inverse computational techniques, leading to highly conformal radiotherapy dose distributions and better sparing of the OARs from high doses, even with complex target shapes containing both concave and convex surfaces. The non-uniform beam intensities are created by a multi leaf collimator (MLC) located in the treatment machine gantry, which shapes and modulates the radiation beam as it exits the linear accelerator. Initially IMRT was delivered using 5 to 9 static beams arranged around the patient, with static (step and shoot) or dynamic (sliding window) MLC configurations [17].

Later, volumetric modulated arc therapy (VMAT) was developed. Our institution has played an important role in the development and clinical implementation of this novel form of IMRT optimization and delivery, which allows the radiation dose to be accurately and efficiently delivered in a single or a few gantry rotations [18, 19]. In VMAT, the dose rate, gantry speed and monitor unit output (MU, i.e. dose pulses) can be varied. Compared with multiple static IMRT beams, VMAT typically gives a reduction in treatment time and number of MUs required to deliver a given fraction size. Another rotational delivery technique is tomotherapy, which can also use a full 360° of beam directions for optimization and treatment, however tomotherapy treatment is given in a slice-by-slice or helical fashion [20].



Conventional plan on left panels: high dose region (red color wash) covers PTV_{boost} (in orange) and PTV_{elective} (in red) but also parotid glands (in purple and green). Volumetric modulated arc therapy plan on right panels: PTV_{boost} in high dose region, parotid glands in low dose region (blue color wash)

Volume definition, dose prescription

The actual treatment of a patient with HNC is preceded by several preparatory steps. All patients are typically discussed in a multi-disciplinary tumor board where the available clinical, imaging and pathology information is reviewed and an initial management recommendation is made. If the patient consents to treatment by CRT, then first of all an immobilization mask is made to ensure accurate and reproducible daily setup (positioning) for precise dose delivery. With the patient in this mask, a planning CT scan is made on which the tumor, lymph nodes and OARs are delineated with additional help from clinical and pathological examination findings, including in some patients an endoscopic examination of the upper aero-digestive tract under anesthesia. The primary tumor with the visibly affected lymph nodes is called the Gross Tumor Volume (GTV); around which a margin for possible microscopic spread is created (boost Clinical Target Volume, CTV_{boost}). The lymph node regions harboring possible microscopic disease are referred to as the elective Clinical Target Volume (CTV_{elective}). Around these volumes, a Planning Target Volume for the elective and high dose boost volumes (PTV_{elective} and PTV_{boost}), typically consisting of a 4 or 5 mm margin around the CTV, is constructed to account for uncertainties in positioning and

movement during treatment [21]. A typical treatment plan aims to give a high dose to the PTV_{boost} and an intermediate dose to the PTV_{elective} (to eradicate possible microscopic disease), while keeping the dose to the various OARs as low as possible. The different doses to the different target volumes can be given in a sequential way. For example, in the primary setting, daily fractions of 2 Gray (Gy) are given to a total dose of 46-50 Gy to both PTVs, followed by a dose of 20-24 Gy to the PTV_{boost} (to a total dose of 70 Gy). An alternative technique, delivering different doses to different target volumes during the same treatment session is called the simultaneous integrated boost (SIB) technique. In the primary setting, a typical dose of 35 fractions of 2 Gy is delivered to the PTV_{boost} and a dose of 35x 1.55 Gy to the PTV_{elective}.

Outline of the thesis

This thesis focuses on the treatment of locally-advanced head and neck cancer with advanced radiotherapy techniques, which have been used to try and improve *functional* organ preservation and increase the personalization of radiation treatment planning so that the patient gets a plan that provides adequate target coverage and good OAR sparing for their particular OAR-target volume geometry.

IMRT has quickly been adopted by many radiation oncology centers for the treatment of HNC due to its ability to better shape intermediate-high dose radiation around tumors and relatively spare surrounding healthy tissue. However, IMRT planning for HNC is labor intensive, and treatment time is prolonged when multiple static fields are used. Another potential downside of static gantry IMRT is the increased number of MUs needed to deliver the dose, resulting in a greater integral body dose, and possibly increasing the risk of development of a second malignancy [22]. With the advent of VMAT, some of these drawbacks could be addressed: using 2 arcs, highly conformal VMAT plans could be created in a relatively short time requiring less MUs and shorter delivery times than conventional IMRT. **Chapter 2** reports on the implementation of RapidArc[®], the VMAT solution from Varian Medical Systems (Palo Alto, CA, USA) for the treatment of locally-advanced HNC.

The use of IMRT and VMAT allowed for a reduction of the parotid gland (PG) dose without compromising target volume coverage. However, the submandibular glands (SMG) are also important and largely responsible for salivary output in unstimulated conditions and the subjective sense of moisture [9]. Since the SMG are located next to the jugulodigastric nodes, which are the first echelon for most HNC tumors, sparing was initially not considered because of fear of underdosing the target volume and compromising local tumor control. **Chapter 3** examines the possibility of sparing the contralateral SMG in patients requiring contralateral elective neck irradiation, without compromising planning target volume (PTV) coverage, using VMAT.

Chapter 4 describes the use of non-coplanar VMAT in the treatment of sinonasal tumors. Achieving a clinically acceptable plan for these tumors is technically challenging because of the location near the optic system. Non-coplanar plans achieved clinically relevant reductions in dose to the visual structures without sacrificing PTV coverage or dose homogeneity.

Concurrent CRT is considered standard of care for non-surgical treatment of locally advanced HNC. Although it remains a controversial area, several studies have examined the use of induction chemotherapy (IC) prior to CRT in advanced stage HNC. Tumor shrinkage before the start of radiotherapy could possibly enable reduced doses to the OARs. **Chapter 5** explores the impact on OAR doses using 2 different delineation strategies, one before and the other after induction chemotherapy.

The use of IMRT and VMAT facilitates increasingly complex treatment planning for HNC: techniques have evolved over the years from essentially parotid gland and spinal cord sparing alone, to include sparing of the submandibular glands, individual swallowing muscles and oral cavity. **Chapter 6** evaluates the impact of progressive sparing of more OARs and the introduction of new planning techniques on plan quality in our department.

With IMRT and VMAT it is possible to reduce the dose to the salivary glands in comparison with 3D conformal RT, leading to less estimated risk of xerostomia (i.e a dry mouth). However, the ipsilateral PG as well as the SMG often still receive a considerable dose, leading to a certain degree of hypo-salivation [23]. The mechanism of salivary gland toxicity is poorly understood and no real interventions for recovery exist. Non-invasive imaging might help to better understand the response of the glands to CRT, which could in turn lead to possible therapeutic strategies. **Chapter 7** examines the effect of CRT on salivary glands using diffusion weighted magnetic resonance imaging (DW-MRI) performed before, during and after CRT.

Although IMRT and/or VMAT have been adopted in all Dutch radiotherapy departments, and national and international guidelines exist, there are differences between centers in the treatment of specific tumor sites like the larynx. **Chapter 8** investigates the current management of T₃ laryngeal cancer in the Netherlands.

Finally, **Chapter 9** summarizes the most important findings of all the chapters and discusses the current status and future directions of advanced radiotherapy techniques in HNC.

References

1. Cancer Facts and figures 2014, American Cancer society, Atlanta, GA, USA
2. website IKNL: <http://www.cijfersoverkanker.nl/nkr/index>
3. Chaturvedi AK, Anderson WF, Lortet-Tieulent J, Curado MP, Ferlay J, Franceschi S, et al. Worldwide trends in incidence rates for oral cavity and oropharyngeal cancers. *J Clin Oncol*. 2013;31:4550–9
4. Belcher R, Hayes K, Fedewa S, Chen AY. Current treatment of head and neck squamous cell cancer. *J Surg Oncol*. 2014;110:551-74
5. Bernier J, Cooper JS, Pajak TF, van Glabbeke M, Bourhis J, Forastiere A, et al. Defining risk levels in locally advanced head and neck cancers: a comparative analysis of concurrent postoperative radiation plus chemotherapy trials of the EORTC (#22931) and RTOG (# 9501). *Head Neck*. 2005;27:843-5
6. The Department of Veterans Affairs Laryngeal Cancer Study Group. Induction chemotherapy plus radiation compared with surgery plus radiation in patients with advanced laryngeal cancer. *N Engl J Med*. 1991;324:1685-90
7. Forastiere AA, Goepfert H, Maor M, Pajak TF, Weber R, Morrison W, et al. Concurrent chemotherapy and radiotherapy for organ preservation in advanced laryngeal cancer. *N Engl J Med*. 2003;349:2091-8
8. Pignon JP, le Maître A, Maillard E, Bourhis J; MACH-NC Collaborative Group. Meta-analysis of chemotherapy in head and neck cancer (MACH-NC): an update on 93 randomised trials and 17,346 patients. *Radiother Oncol*. 2009;92:4-14
9. Dirix P, Nuyts S. Evidence-based organ-sparing radiotherapy in head and neck cancer. *Lancet Oncol*. 2010;11:85-9
10. Xu CJ, van der Schaaf A, Van't Veld AA, Langendijk JA, Schilstra C. Statistical validation of normal tissue complication probability models. *Int J Radiat Oncol Biol Phys*. 2012;84:e123-9
11. Cox JD, Stetz J, Pajak TF. Toxicity criteria of the Radiation Therapy Oncology Group (RTOG) and the European Organization for Research and Treatment of Cancer (EORTC). *Int J Radiat Oncol Biol Phys*. 1995;31:1341-6
12. Salama JK, Seiwert TY, Vokes EE. Chemoradiotherapy for locally advanced head and neck cancer. *J Clin Oncol*. 2007;25:4118-26
13. Verdonck-de Leeuw IM, Buffart LM, Heymans MW, Rietveld DH, Doornaert P, de Bree R, et al. The course of health-related quality of life in head and neck cancer patients treated with chemoradiation: a prospective cohort study. *Radiother Oncol*. 2014;110:422-8
14. Maes A, Weltens C, Flamen P, Lambin P, Bogaerts R, Liu X et al. Preservation of parotid function with uncomplicated conformal radiotherapy. *Radiother Oncol*. 2002;63:203-11.
15. Eisbruch A, Ship JA, Martel MK, Ten Haken RK, Marsh LH, Wolf CT, et al. Parotid gland sparing in patients undergoing bilateral head and neck irradiation: techniques and early results. *Int J Radiat Oncol Biol Phys*. 1996;36:469-80
16. Intensity Modulated Radiation Therapy Collaborative Working Group. Intensity-modulated radiotherapy: current status and issues of interest. *Int J Radiat Oncol Biol Phys*. 2001;51:880-914
17. Galvin JM, Ezzell G, Eisbruch A, Yu C, Butler B, Xiao Y, et al. Implementing IMRT in clinical practice: a joint document of the American Society for Therapeutic Radiology and Oncology and the American Association of Physicists in Medicine. *Int J Radiat Oncol Biol Phys*. 2004;58:1616–34
18. Verbakel WF, Senan S, Lagerwaard FJ, Cuijpers JP, Slotman BJ. Comments on 'Single-Arc IMRT?'. *Phys Med Biol*. 2009;54:L31-4; author reply L35-6
19. Verbakel WF, Cuijpers JP, Hoffmans D, Bieker M, Slotman BJ, Senan S. Volumetric intensity-modulated arc therapy vs. conventional IMRT in head-and-neck cancer: a comparative planning and dosimetric study. *Int J Radiat Oncol Biol Phys*. 2009;74:252-9

20. Palma DA, Verbakel WF, Otto K, Senan S. New developments in arc radiation therapy: a review. *Cancer Treat Rev.* 2010;36:393-9
21. Grégoire V, Mackie TR. State of the art on dose prescription, reporting and recording in Intensity-Modulated Radiation Therapy (ICRU report No. 83). *Cancer Radiother.* 2011;15:555-9
22. E.J. Hall, C.-S. Wu, Radiation-induced second cancers: The impact of 3D-CRT and IMR. *Int J Radiat Oncol Biol Phys.* 2003;56:83-8
23. Deasy JO, Moiseenko V, Marks L, Chao KS, Nam J, Eisbruch A. Radiotherapy dose-volume effects on salivary gland function. *Int J Radiat Oncol Biol Phys.* 2010;76:S58-63.