



Chapter 8

Dementia mimicking Alzheimer's disease due to a tau mutation: CSF and PET findings

Nelleke Tolboom, Esther L.G.E. Koedam, Jonathan M. Schott
Maqsood Yaqub, Marinus A. Blankenstein, Frederik Barkhof
Yolande A.L. Pijnenburg, Adriaan A. Lammertsma, Philip Scheltens
Bart N.M. van Berckel

Alzheimer Disease and Associated Disorders, in press.



Abstract

Objective: To illustrate the utility of positron emission tomography (PET) imaging using [^{11}C]PIB and [^{18}F]FDDNP, together with cerebrospinal fluid (CSF) measures of amyloid- β 1-42 (A β 42), total tau (t-tau) and tau phosphorylated at threonine 181 (p-tau) in the *in vivo* diagnosis of specific dementia syndromes.

Methods: Two siblings fulfilling diagnostic criteria for familial Alzheimer's disease (AD) were investigated using [^{11}C]PIB and [^{18}F]FDDNP PET, in combination with CSF measures of A β 42, t-tau and p-tau. PET data were compared with paired [^{11}C]PIB and [^{18}F]FDDNP data from age matched sporadic AD patients (n=9) and healthy controls (n=6).

Results: [^{11}C]PIB retention and CSF levels of A β 42 in both patients resembled those of controls, suggesting the presence of non-amyloid pathology. Genetic testing confirmed the absence of mutations in the *presenilin 1* gene in one patient; subsequent testing revealed the R406W *tau* mutation in both individuals leading to a diagnosis of frontotemporal dementia (FTD). [^{18}F]FDDNP retention broadly correlated with CSF levels of t-tau and p-tau. Despite both individuals harbouring the same mutation, [^{18}F]FDDNP retention and CSF t-tau and p-tau were elevated in one patient but not in the other.

Conclusion: [^{11}C]PIB imaging and CSF measures of A β 42 are useful in refuting the presence of underlying amyloid pathology. This, in combination with elevated levels of CSF t-tau and p-tau, has potential value in differential diagnosis of FTD from AD.



Introduction

The prospect of disease modifying drugs for Alzheimer's disease (AD) means that distinguishing AD both from normal ageing and from different forms of dementia is becoming increasingly important. Potential *in vivo* biomarkers of AD pathology including positron emission tomography (PET) with amongst others, [¹¹C]PIB (1) and [¹⁸F]FDDNP (2), and cerebrospinal fluid (CSF) analysis (3) are thus the subject of intense study and ongoing validation. Of these, [¹¹C]PIB binding reflects cerebral A β load (1), and [¹⁸F]FDDNP binding is thought to reflect both A β plaque and tangle load (2). Reduction of amyloid- β 1-42 (A β 42) and increase in levels of total tau (t-tau) and tau phosphorylated at threonine 181 (p-tau) in CSF have been shown to be of diagnostic value in AD (3).

Patients with confirmed genetic mutations leading to autosomal dominant inherited dementia syndromes provide a unique opportunity to examine the specificity of such biomarkers *in vivo*. In this report we describe two siblings with progressive cognitive deterioration clinically resembling AD in whom biomarkers suggested the absence of underlying amyloid pathology, a suspicion subsequently confirmed by the identification of the R406W *tau* mutation, leading to a diagnosis of frontotemporal dementia (FTD) (4).

Methods

Subjects

Two siblings with an AD clinical phenotype were included in this imaging study. Six patients fulfilling criteria for probable sporadic AD, and nine healthy controls were used to provide normative imaging data (5). All subjects received a standard dementia screening including medical history, physical and neurological examinations, screening laboratory tests, brain MRI, and neuropsychological testing. Clinical diagnosis was established according to standard consensus criteria in a multidisciplinary meeting. All AD patients met NINCDS-ADRDA (6) criteria for probable AD. Written informed consent was obtained from all subjects. The study was approved by the Medical Ethics Review Committee of the VU University Medical Centre Amsterdam.

CSF analysis

CSF A β 42, t-tau and p-tau were measured with Innostest (Innogenetics, Ghent, Belgium) sandwich ELISAs as described previously (3).

Positron emission tomography

Dynamic 90 minutes [¹¹C]PIB and [¹⁸F]FDDNP PET scans were performed as described previously (5) after injection of approximately 390 MBq [¹¹C]PIB with a specific activity (SA) of 41 GBq/ μ mol and 194 MBq [¹⁸F]FDDNP with an SA of 35 GBq/ μ mol. [¹¹C]PIB and [¹⁸F]FDDNP parametric images of binding potential (BP_{ND}), a quantitative measure of specific binding, were



generated using cerebellar grey matter as reference tissue. For regional analyses, the volume weighted average BP_{ND} of frontal, parietal and temporal cortex, medial temporal lobe (MTL) and posterior cingulate was calculated. A global cortical region of interest (ROI) was defined as the volume weighted average of all aforementioned regions. PET results were compared with paired [^{11}C]PIB and [^{18}F]FDDNP data of age matched AD patients and healthy controls included in a previous study (5).

Genetic testing

Following appropriate counselling, testing for specific mutations in presenilin 1, the gene most frequently associated with familial AD was performed in patient 1; screening for mutations in the tau gene was subsequently performed in both patients. Exon 13 of MAPT including intron/exon boundaries was amplified from genomic DNA according to the following conditions (7): reaction volume was 15 μ l, with a final concentration of 10 mM Tris-HCL (pH8.3), 50 mM KCl, 1,5 mM MgCl₂, and 250 μ M dNTPS; Platinum Taq polymerase at 0,35 units/15 μ l; primers at 10pmol/ μ l and 15 ng template genomic DNA. PCR reactions were sequenced in both strands and run on an automated DNA sequencer (ABI 3730).

Results

Patient 1

The patient was a 61-year-old man who complained of progressive episodic memory impairment since seven years. There was a positive family history of dementia: his grandfather, father, two uncles and one aunt on his father's side all had developed dementia prior to the age of 60. The Mini Mental State Examination (MMSE) score was 29/30. Magnetic resonance

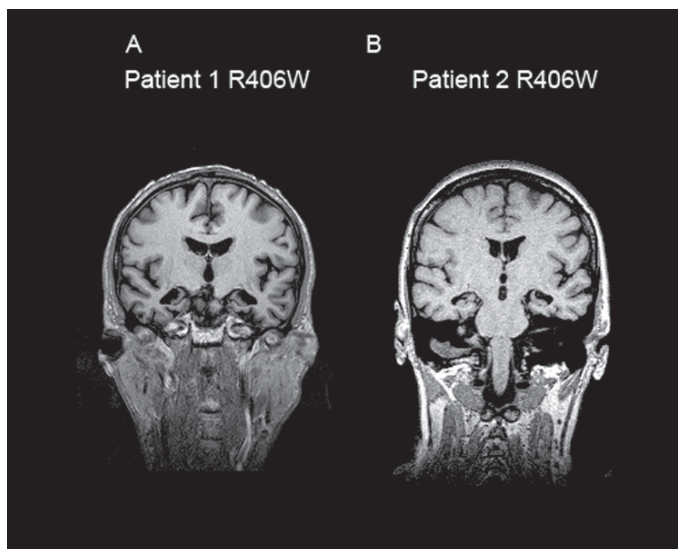


Figure 1: Coronal MRI in R406W mutation patients
Figure 1 illustrates severe, strictly isolated, symmetrical medial temporal lobe atrophy in patients 1 (panel A) and 2 (panel B).

imaging (MRI) of the brain revealed pronounced isolated bilateral, symmetrical medial temporal lobe atrophy, especially in the anterior part (Figure 1 A). Neuropsychological testing revealed problems with registration and retention of verbal information and poor face recognition, with no impairment on executive functions. A clinical diagnosis of amnesic MCI (8), probably due to incipient familial AD, was made.

Patient 2

Concurrently, the patient's sister, a 59 year old woman, also sought medical attention for evaluation of cognitive decline. She presented with similar, but more severe complaints than her brother, leading to interference of activities of daily living. The MMSE score was 26/30. MRI of the brain revealed a similar, though more profound, pattern of selective hippocampal atrophy (Figure 1 B). Neuropsychological testing revealed problems with registration and retention

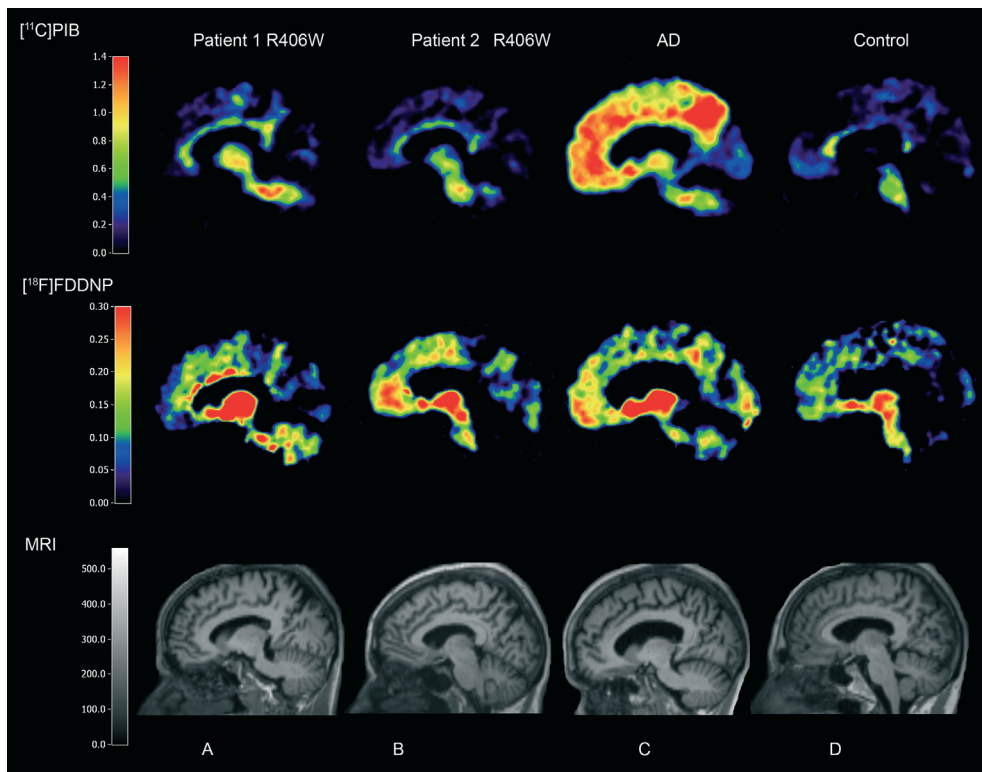


Figure 2: $[^{11}\text{C}]\text{PIB}$ and $[^{18}\text{F}]\text{FDDNP}$ PET and MRI in R406W mutation patients together with AD and control

Panel A=patient 1, B=patient 2, C=Alzheimer's disease patient, D=healthy control. Normal $[^{11}\text{C}]\text{PIB}$ retention in panels A, B and D. Panel C displays high $[^{11}\text{C}]\text{PIB}$ retention in frontal and parietal regions. Normal $[^{18}\text{F}]\text{FDDNP}$ retention in panels A and D. Panels B and C display higher frontal $[^{18}\text{F}]\text{FDDNP}$ retention with more diffuse $[^{18}\text{F}]\text{FDDNP}$ uptake in panel C.

of verbal information, with no impairment on executive functions. A clinical diagnosis of AD, probably due to familial AD, was made.

CSF

A lumbar puncture was performed at the initial visit for both patients. CSF A β 42 levels were within normal limits (patient 1: 933 pg/ml, normal range (3) (NR)>495 pg/ml; patient 2: 1026 pg/ml). T-tau and p-tau levels were normal in patient 1 (340 pg/ml, NR<356 pg/ml and 51 pg/ml, NR<54 pg/ml, respectively). Both were elevated in patient 2 (t-tau: 442 pg/ml; p-tau 63 pg/ml)

[¹¹C]PIB and [¹⁸F]FDDNP PET

Twenty months after first clinical assessment, patient 1 underwent an [¹¹C]PIB PET scan and thirteen months thereafter, an [¹⁸F]FDDNP PET scan was performed. Thirty-three months after first assessment, patient 2 underwent paired [¹¹C]PIB and [¹⁸F]FDDNP PET scans. Visual inspection of parametric [¹¹C]PIB images did not reveal abnormal tracer accumulation; inspection of parametric [¹⁸F]FDDNP images revealed an indistinct pattern of retention in both siblings (Figure 2, panel A and B). Global and regional [¹¹C]PIB and [¹⁸F]FDDNP binding of the 2 siblings was compared with paired [¹¹C]PIB and [¹⁸F]FDDNP data of six AD patients (age 62 \pm 4 years, MMSE 24 \pm 3) and nine healthy controls (age 61 \pm 3 years, MMSE 30 \pm 1) (5). Global and regional [¹¹C]PIB uptake of both patients was similar to that of controls. Patient 1 displayed low [¹⁸F]FDDNP uptake, both compared to controls and AD; Patient 2 had an intermediate level of binding, lying within the range of both AD patients and controls (Figure 3). Patient 1 had higher [¹⁸F]FDDNP binding than seen in the AD group in the medial temporal lobe; whilst patient 2 displayed increased binding, similar to mean binding in AD, in frontal and parietal lobes and posterior cingulate (Table 1).

Table 1: Regional [¹¹C]PIB and [¹⁸F]FDDNP binding data by diagnostic group

Diagnosis	[¹¹ C]PIB BP _{ND}				[¹⁸ F]FDDNP BP _{ND}			
	Controls	Patient 1	Patient 2	AD	Controls	Patient 1	Patient 2	AD
Brain region								
Global	0.03 \pm 0.03	0.02	-0.02	0.90 \pm 0.12	0.06 \pm 0.02	0.04	0.07	0.09 \pm 0.02
Frontal	0.01 \pm 0.04	0.01	-0.02	0.97 \pm 0.10	0.05 \pm 0.02	0.04	0.09	0.09 \pm 0.03
Medial temporal	0.04 \pm 0.02	-0.03	-0.10	0.17 \pm 0.08	0.11 \pm 0.02	0.20	0.05	0.15 \pm 0.06
Temporal	0.04 \pm 0.03	0.04	-0.02	0.82 \pm 0.11	0.07 \pm 0.03	0.05	0.07	0.10 \pm 0.03
Posterior cingulate	0.07 \pm 0.04	0.04	0.02	0.87 \pm 0.25	0.04 \pm 0.05	0.00	0.07	0.07 \pm 0.06
Parietal	0.04 \pm 0.02	0.00	-0.02	1.01 \pm 0.23	0.03 \pm 0.01	-0.02	0.05	0.06 \pm 0.02

Data are presented as mean \pm SD.

AD, Alzheimer's disease; BP_{ND}, binding potential

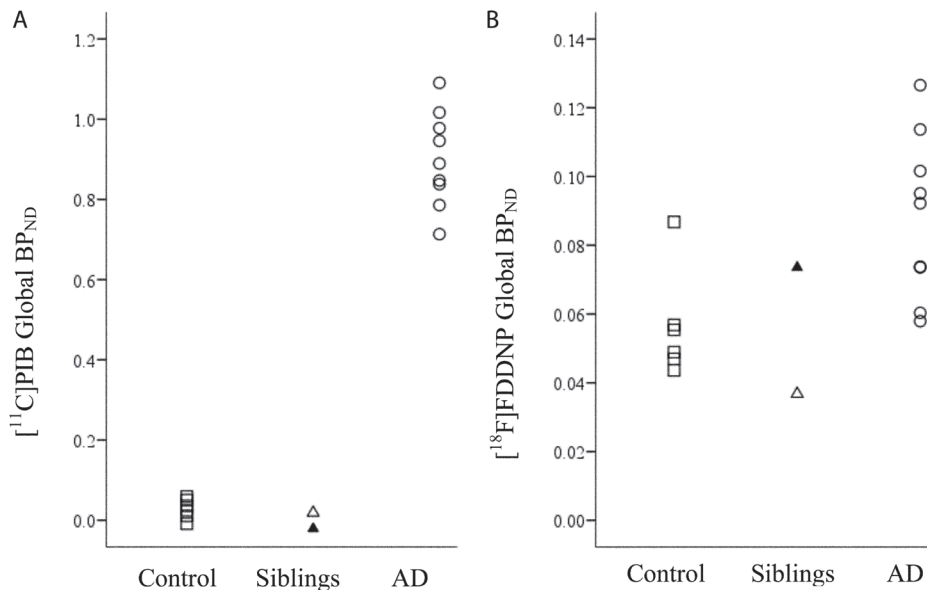


Figure 3: Scatter plots of global cortical $[^{11}\text{C}]\text{PIB}$ and $[^{18}\text{F}]\text{FDDNP}$ binding. Scatter plots of global $[^{11}\text{C}]\text{PIB}$ (A) and $[^{18}\text{F}]\text{FDDNP}$ (B) BP_{ND} by diagnostic group (controls: open squares; AD=Alzheimer's disease: open circles; siblings: open triangle for patient 1 and closed triangle for patient 2).

Genetic testing

No specific mutations in the presenilin 1 gene were found in patient 1; subsequent screening revealed the R406W *tau* mutation in both patients.

Discussion

By studying patients with rare autosomal dominantly inherited dementias, in whom a definitive diagnosis can be made *in vivo*, the specificity of biomarkers can be tested. This study illustrates the power of CSF and $[^{11}\text{C}]\text{PIB}$ PET in refuting the presence of amyloid pathology in patients fulfilling the clinical criteria of AD. Moreover, it reveals the potential value of the combination of biomarkers for the differential diagnosis of (sporadic) FTD from AD. Elevated levels of CSF t-tau and p-tau values together with normal $[^{11}\text{C}]\text{PIB}$ imaging and CSF measures of A β 42 have proven to be highly suggestive of FTD.

In the two patients described, the clinical phenotype of slowly progressive episodic memory loss with profound hippocampal atrophy, is in line with previous reports on patients with FTD due to the R406W *tau* mutation (910). Normal $[^{11}\text{C}]\text{PIB}$ uptake and CSF A β 42 corresponds with the neuropathology typically associated with this mutation, i.e. neurofibrillary tangles in the absence of A β plaques (11-14), although concomitant presence of numerous plaques has been reported in two subjects (915).

Although the $[^{18}\text{F}]\text{FDDNP}$ results in the two patients were not conclusive, the findings did

provide additional information regarding binding of this ligand. The apparently low levels of cerebral amyloid in these patients suggests that any [^{18}F]FDDNP retention reflects binding to a substrate other than amyloid. Moreover, differences in global and regional [^{18}F]FDDNP binding between the two patients were, at least to some extent, mirrored by CSF p-tau and t-tau levels. The latter is in line with the strong positive association between global [^{18}F]FDDNP binding and increased CSF tau levels in AD (16).

Acknowledgements

This work was financially supported by ISAO (grant 05512) and AHAF (grant A2005-026). Dr Schott is in receipt of a HEFCE/NHS Clinical Senior Lectureship Award.

We would like to thank Patrizia Rizzu for the information on the genetic screening, the staff of the Division of Nuclear Medicine & PET Research for tracer production and acquisition of PET data, and the technology staff of the Department of Radiology for acquisition of the MRI data. All authors, except JS, had full access to all of the data in the study and take responsibility for the integrity of the data and the accuracy of the data analysis.

References

1. Klunk WE, Engler H, Nordberg A et al. Imaging brain amyloid in Alzheimer's disease with Pittsburgh Compound-B. *Ann Neurol* 2004;55:306-319.
2. Small GW, Kepe V, Ercoli LM et al. PET of brain amyloid and tau in mild cognitive impairment. *N Engl J Med* 2006;355:2652-2663.
3. Schoonenboom NS, Pijnenburg YA, Mulder C et al. Amyloid beta(1-42) and phosphorylated tau in CSF as markers for early-onset Alzheimer disease. *Neurology* 2004;62:1580-1584.
4. Hutton M, Lendon CL, Rizzu P et al. Association of missense and 5'-splice-site mutations in tau with the inherited dementia FTDP-17. *Nature* 1998;393:702-705.
5. Tolboom N, Yaqub M, van der Flier WM et al. Detection of Alzheimer Pathology In Vivo Using Both 11C-PIB and 18F-FDDNP PET. *J Nucl Med* 2009;50:191-197.
6. McKhann G, Drachman D, Folstein M et al. Clinical diagnosis of Alzheimer's disease: report of the NINCDS-ADRDA Work Group under the auspices of Department of Health and Human Services Task Force on Alzheimer's Disease. *Neurology* 1984;34:939-944.
7. Rizzu P, Van Swieten JC, Joosse M et al. High prevalence of mutations in the microtubule-associated protein tau in a population study of frontotemporal dementia in the Netherlands. *Am J Hum Genet* 1999;64:414-421.
8. Petersen RC, Parisi JE, Dickson DW et al. Neuropathologic features of amnesic mild cognitive impairment. *Archives of Neurology* 2006;63:665-672.
9. Lindquist SG, Holm IE, Schwartz M et al. Alzheimer disease-like clinical phenotype in a family with FTDP-17 caused by a MAPT R406W mutation. *Eur J Neurol* 2008;15:377-385.
10. Ostojic J, Elfgren C, Passant U et al. The tau R406W mutation causes progressive presenile dementia with bitemporal atrophy. *Dement Geriatr Cogn Disord* 2004;17:298-301.
11. Reed LA, Grabowski TJ, Schmidt ML et al. Autosomal dominant dementia with widespread neurofibrillary tangles. *Ann Neurol* 1997;42:564-572.
12. Van Swieten JC, Stevens M, Rosso SM et al. Phenotypic variation in hereditary frontotemporal dementia with tau mutations. *Ann Neurol* 1999;46:617-626.
13. Saito Y, Geyer A, Sasaki R et al. Early-onset, rapidly progressive familial tauopathy with R406W mutation. *Neurology* 2002;58:811-813.
14. Mott RT, Dickson DW, Trojanowski JQ et al. Neuropathologic, biochemical, and molecular characterization of the frontotemporal dementias. *J Neuropathol Exp Neurol* 2005;64:420-428.
15. Rosso SM, Kamphorst W, Ravid R, Van Swieten JC. Coexistent tau and amyloid pathology in hereditary frontotemporal dementia with tau mutations. *Ann N Y Acad Sci* 2000;920:115-119.
16. Tolboom N, Flier WMvd, Yaqub M et al. Relationship of cerebrospinal fluid markers to [11C]PIB and [18F]FDDNP binding. *J Nucl Med* 2009;50:1464-1470.

